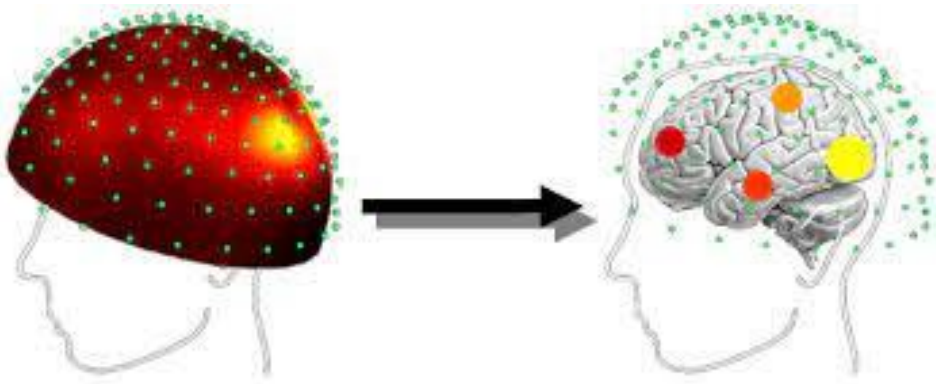


PROGETTI PER LO SVILUPPO DELLA RICERCA: EEG - analisi della sorgente



Lorenzo Ferri

IRCCS Istituto delle scienze Neurologiche di Bologna

Dipartimento di Scienze Biomediche e Neuromotorie

Aula Magna
Viale Aldo Moro, 30
Bologna

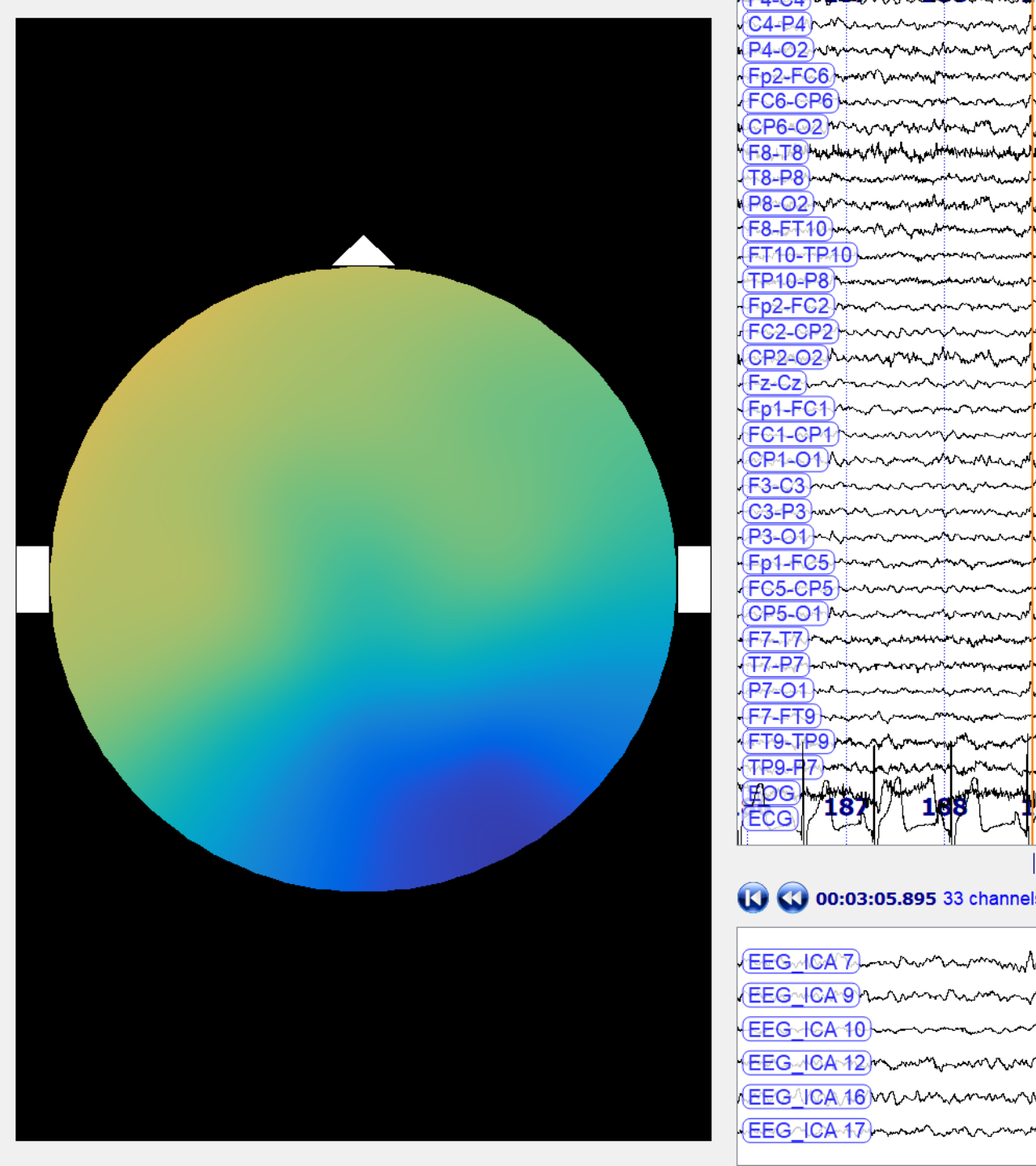
VENERDI' 22 SETTEMBRE 2023

LA CHIRURGIA DELL'EPILESSIA
REGIONE EMILIA- ROMAGNA
19-2022

INCONTRO TRA PROFESSIONISTI

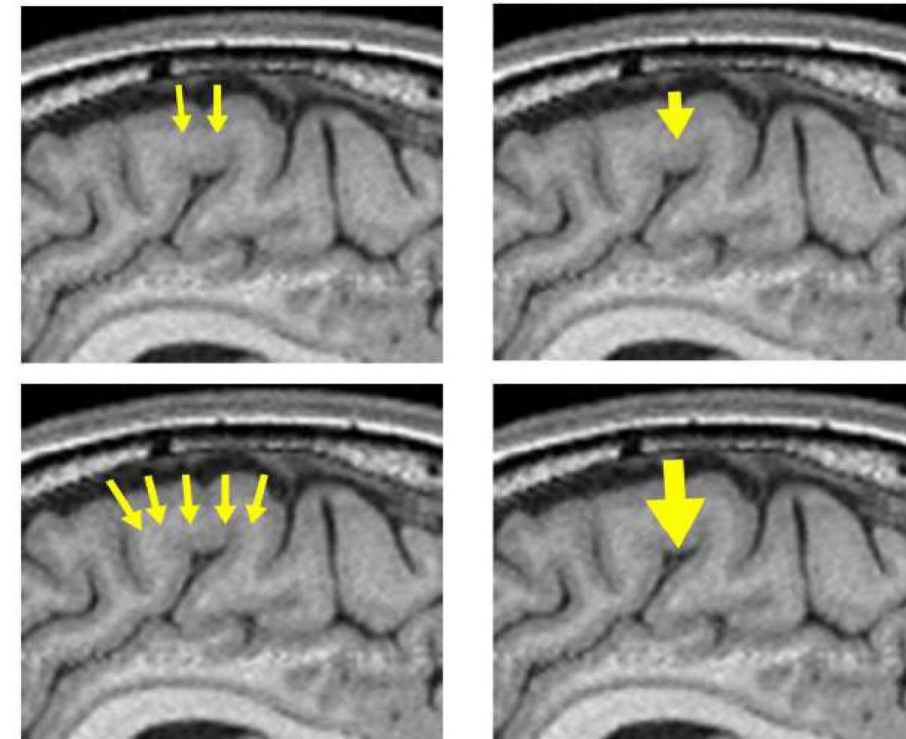
Outline

- Segnale EEG: principi fisiologici e localizzatori
- Electric Source Imaging: tecnica
- ESI applicazioni
- ESI ricerca



Segnale EEG: principi fisiologici e localizzatori

Figure 2

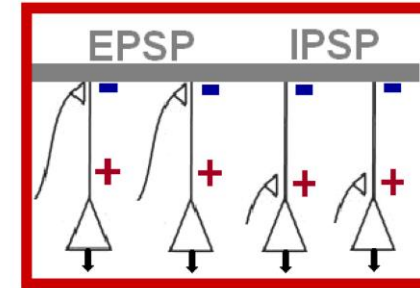


Small area

**Larger area:
Equivalent dipole is stronger
Location is slightly deeper**

Current dipoles with the same orientation within a cortical area summate. The small yellow arrows on the left side symbolize the many, tiny current dipoles of the active cortical columns. They summate like spatial vectors and can be very accurately represented by an equivalent dipole (large yellow arrow on the right).

Figure 1



Schematic representation of post-synaptic potentials at pyramidal cells. Excitatory postsynaptic potentials (EPSP) at the apical dendrites induce negativity in the extracellular space, close to the cortical surface; the return currents create the corresponding positivity, towards the white matter. Inhibitory postsynaptic potentials (IPSP) at the cell body induce positivity in the extracellular space; the return currents create the negativity towards the cortical surface.

In both cases, the current flow creates a dipolar potential distribution, with negativity at the cortical surface and positivity towards the white matter. This orientation of the polarity is typical for epileptiform discharges.



Figure 6 A

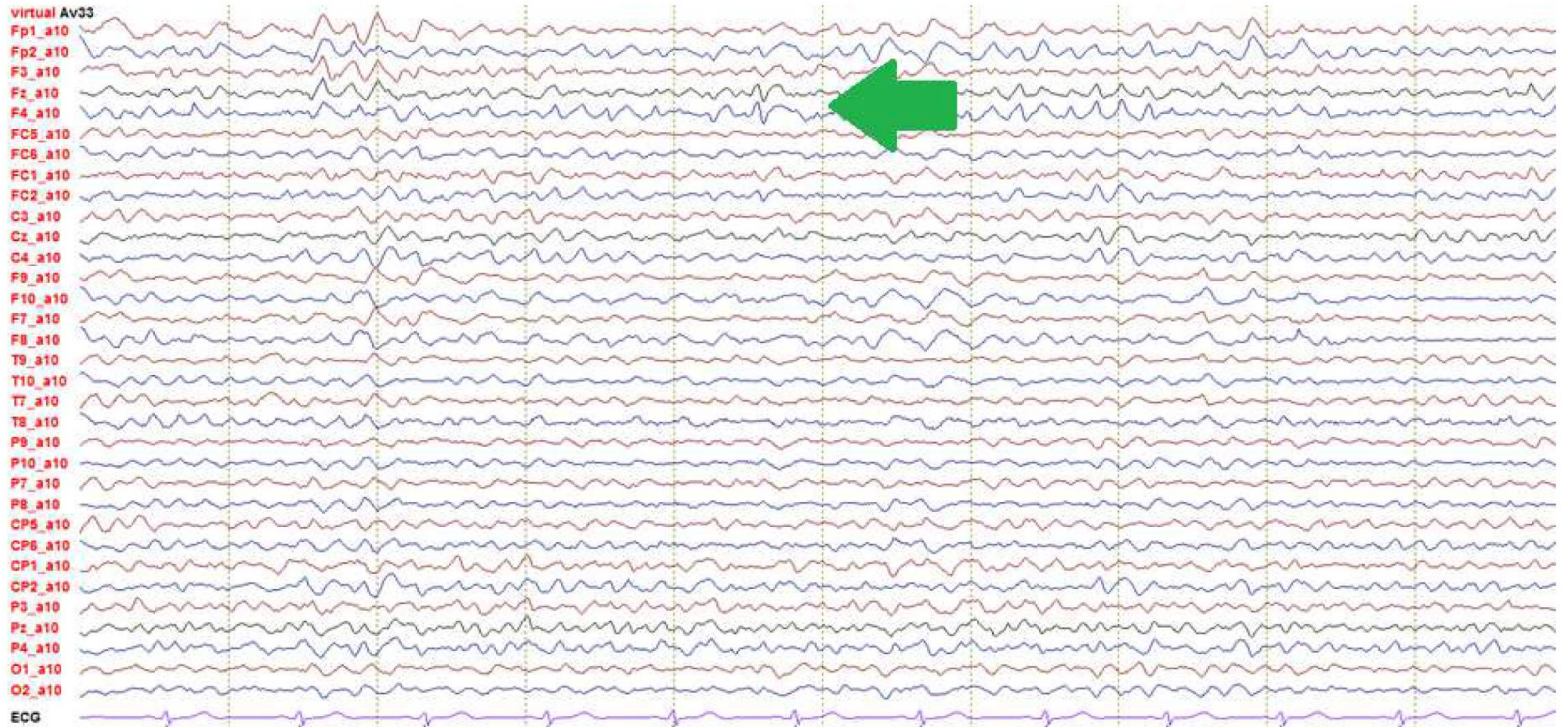
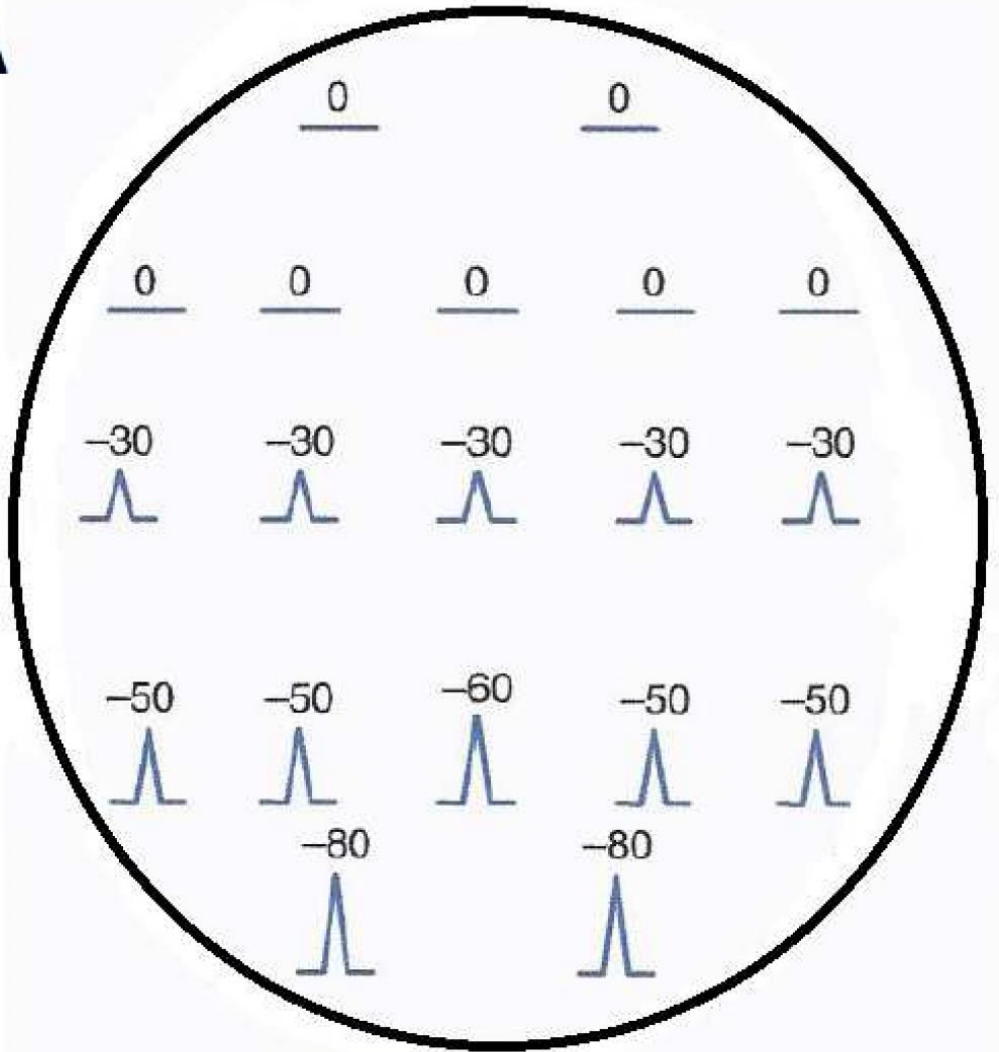
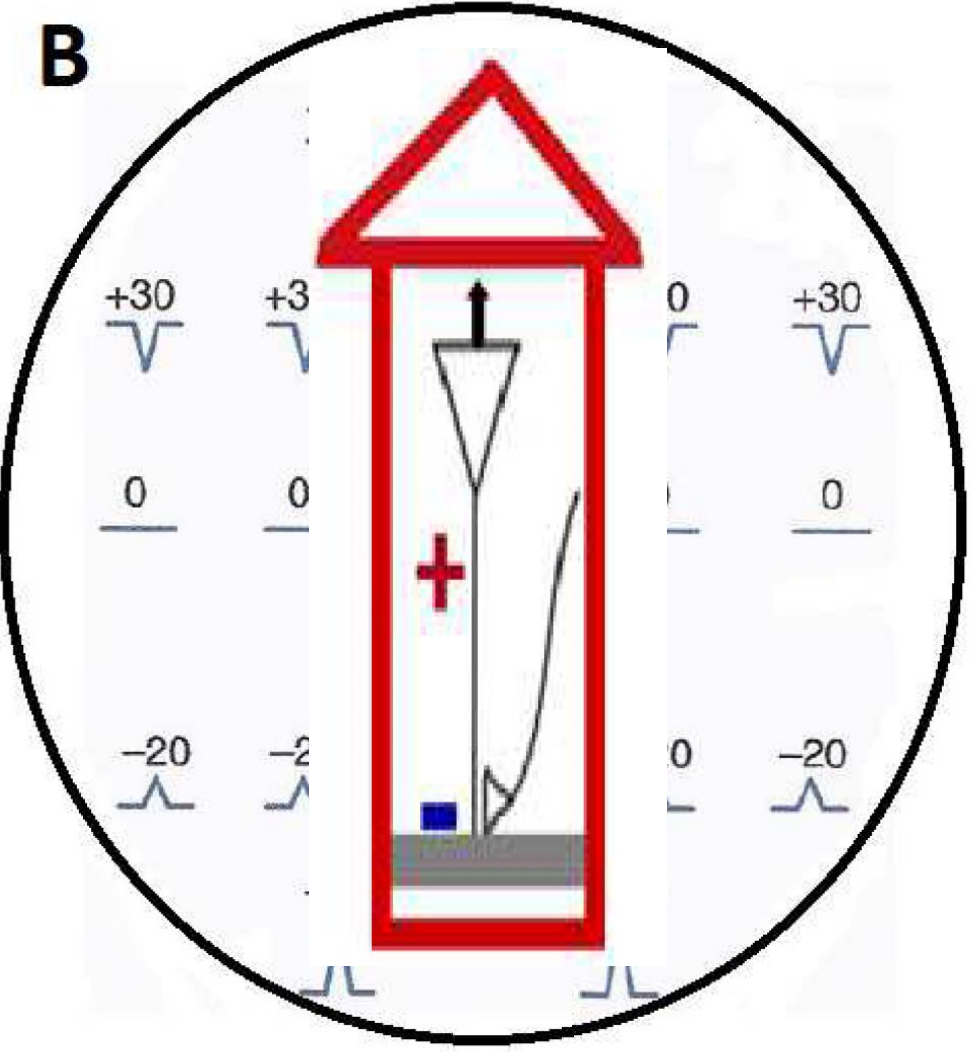


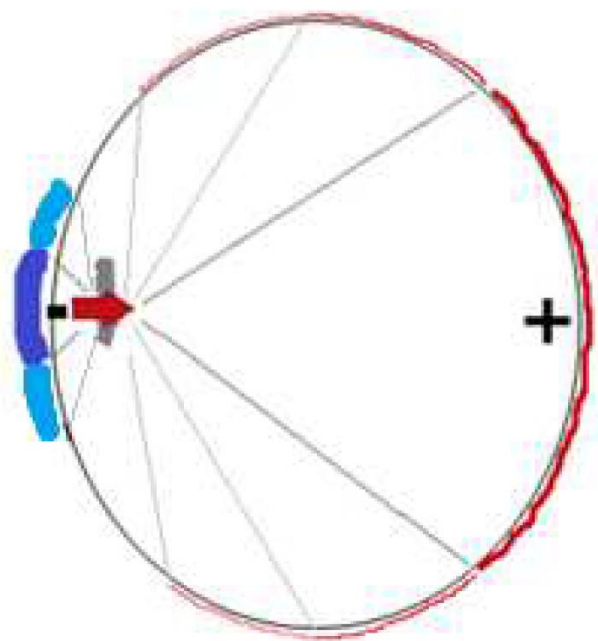
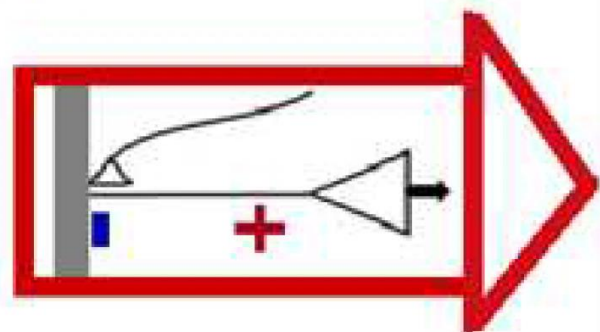
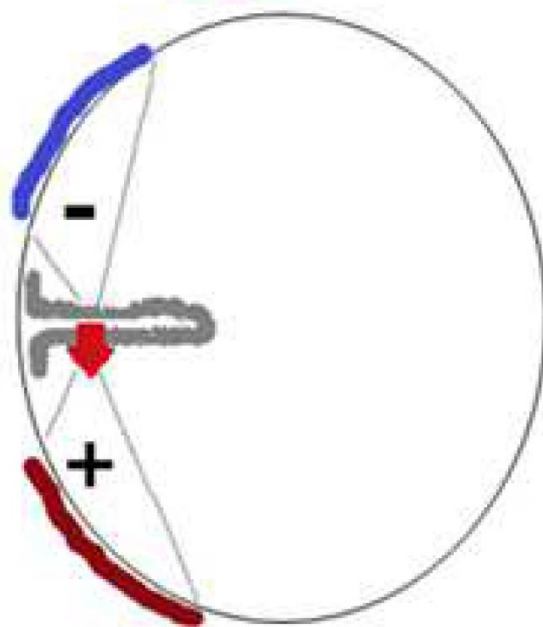
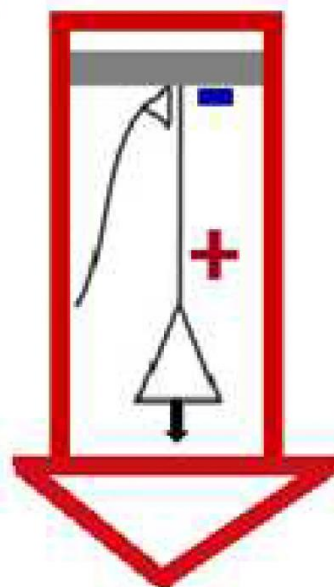
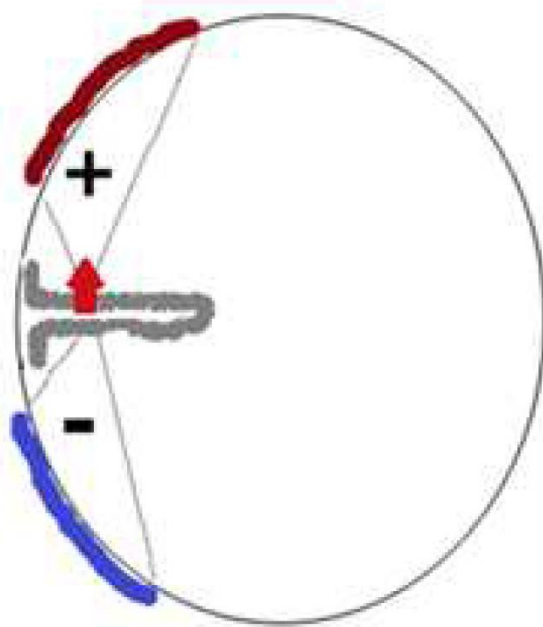
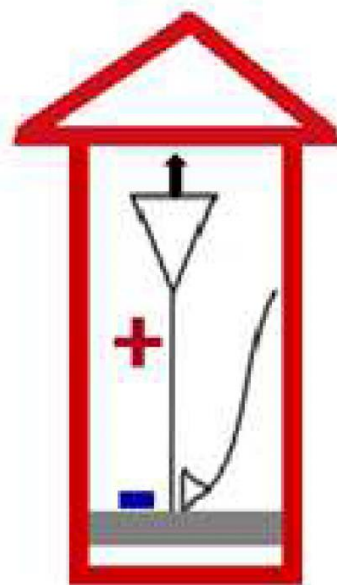
Figure 5

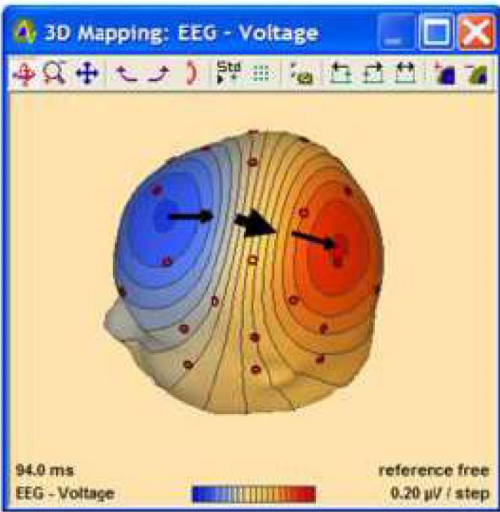
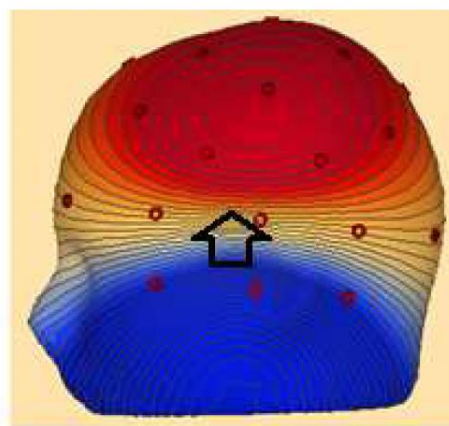
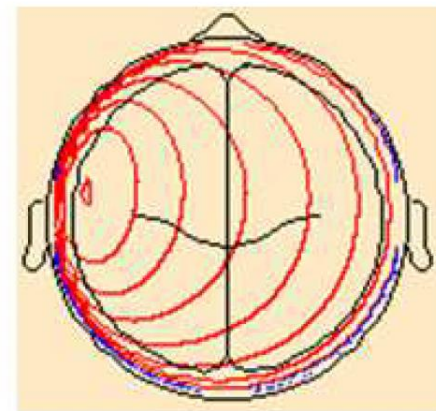
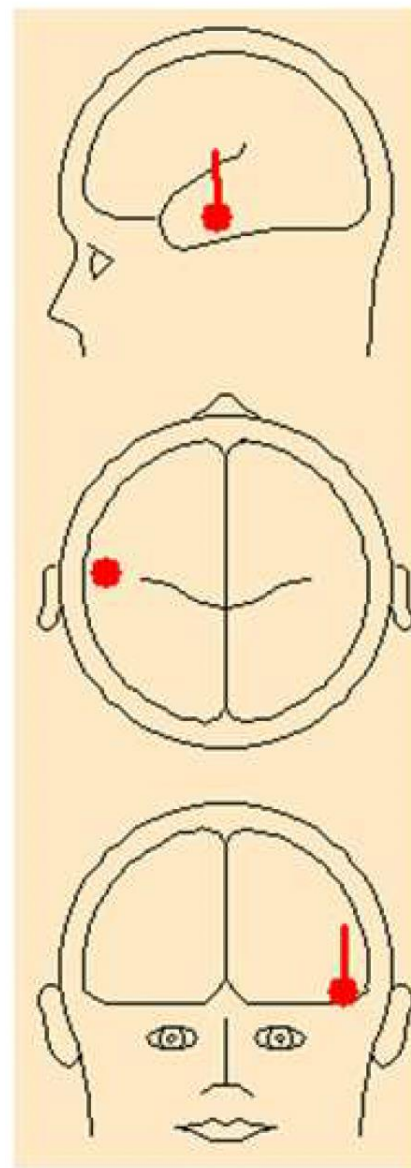
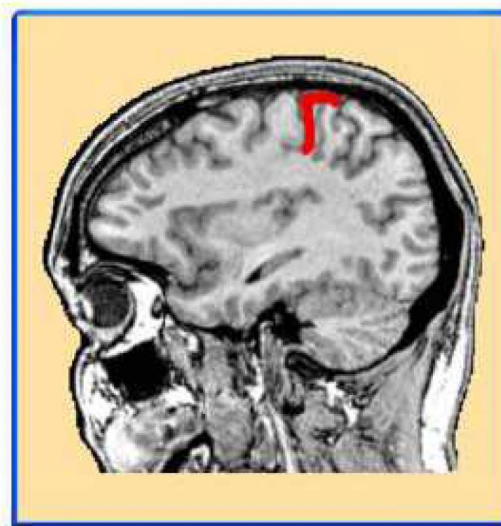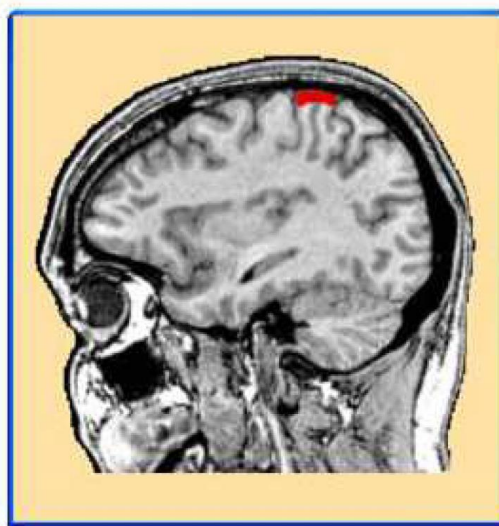
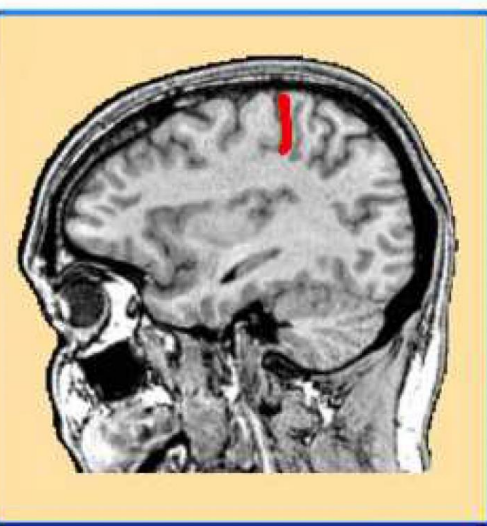
A



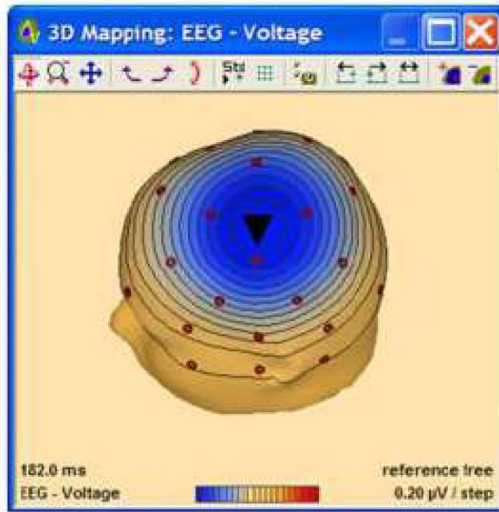
B



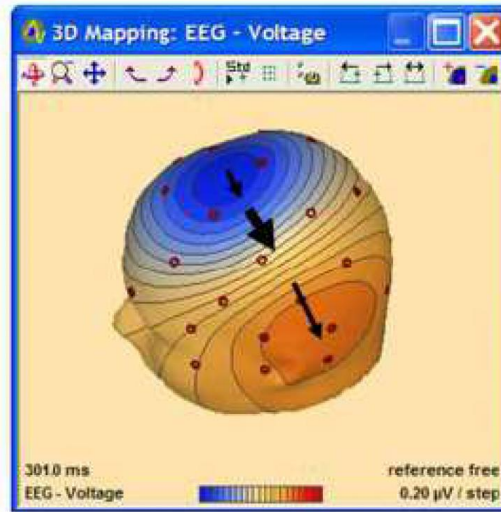
A**B****C**



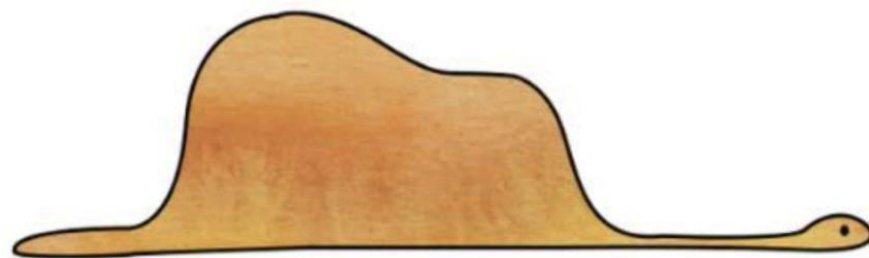
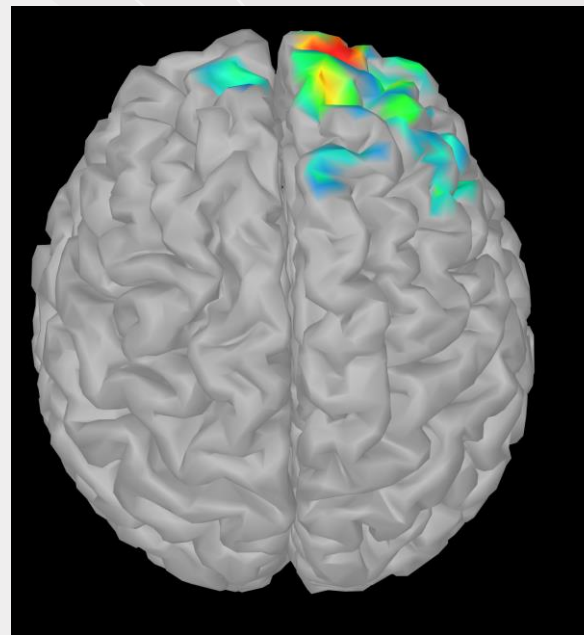
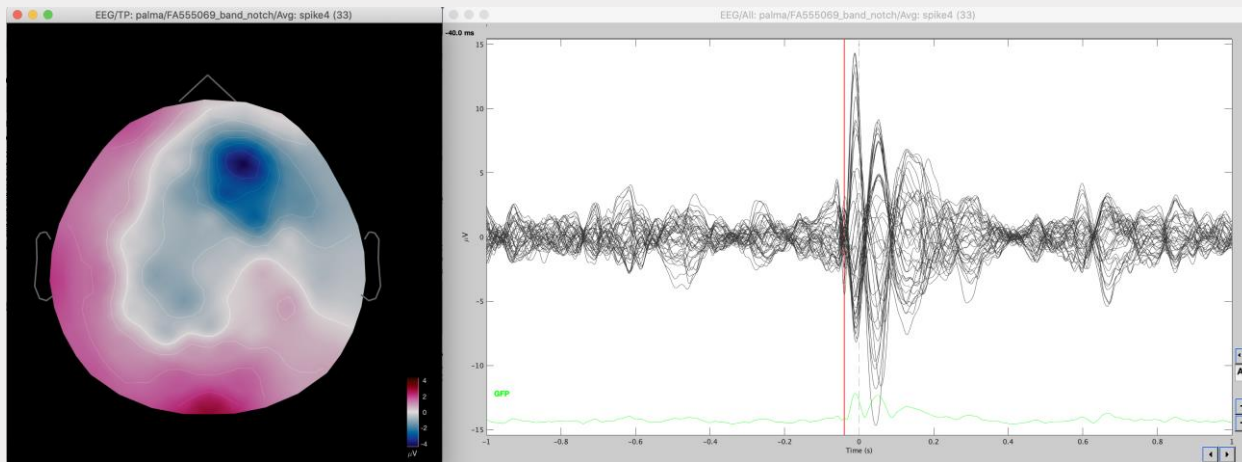
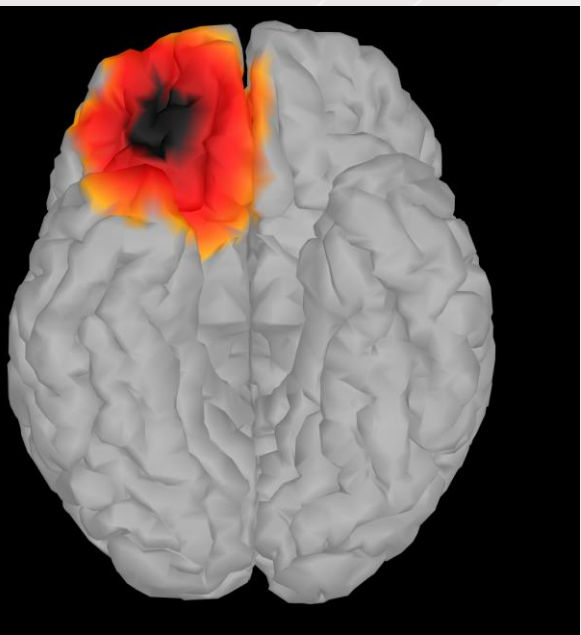
tangential - sulcus



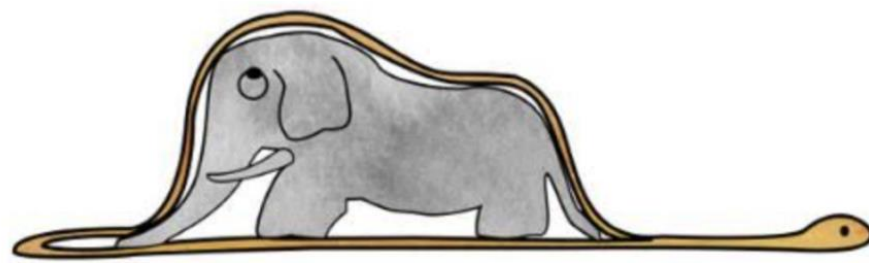
radial - surface



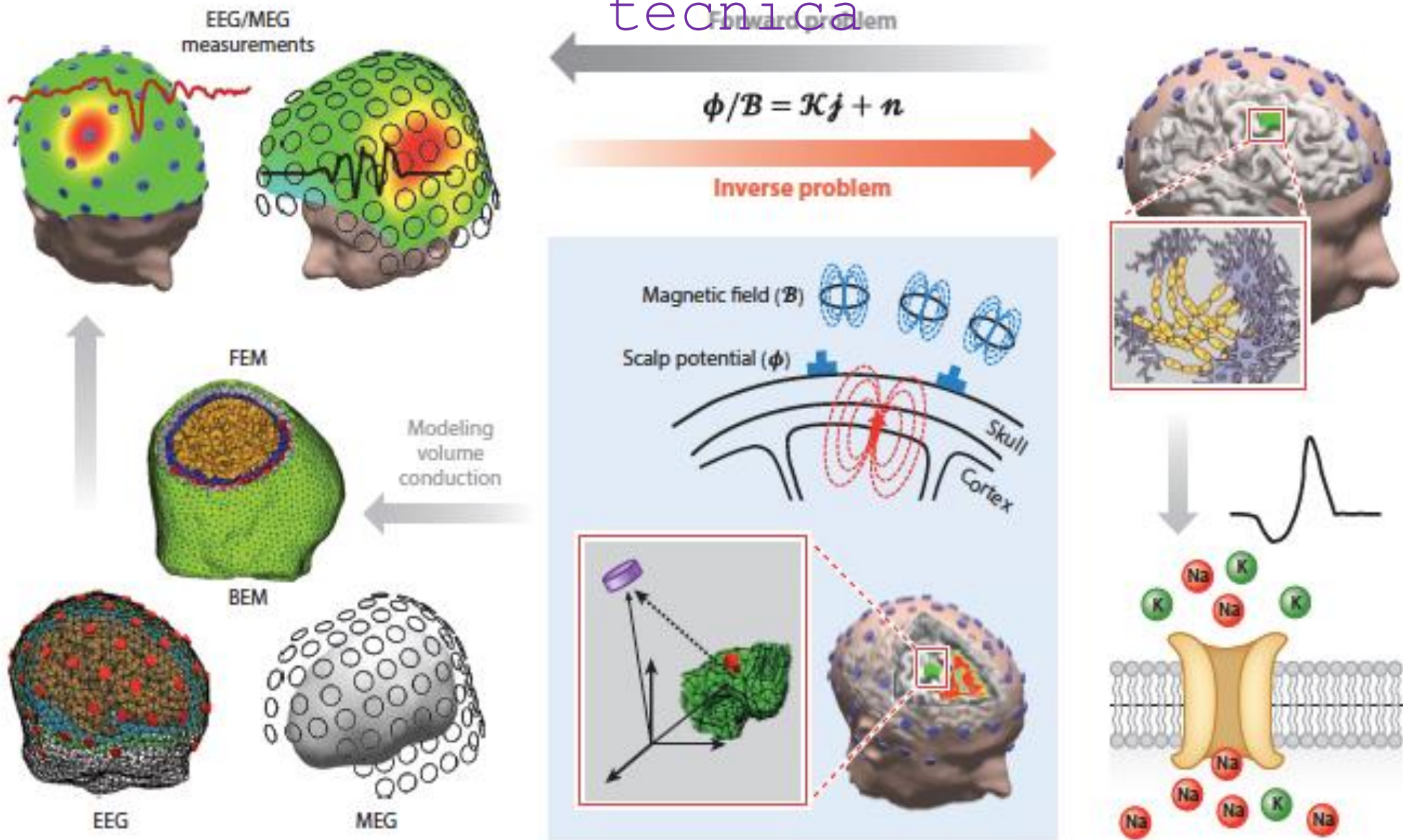
oblique - both



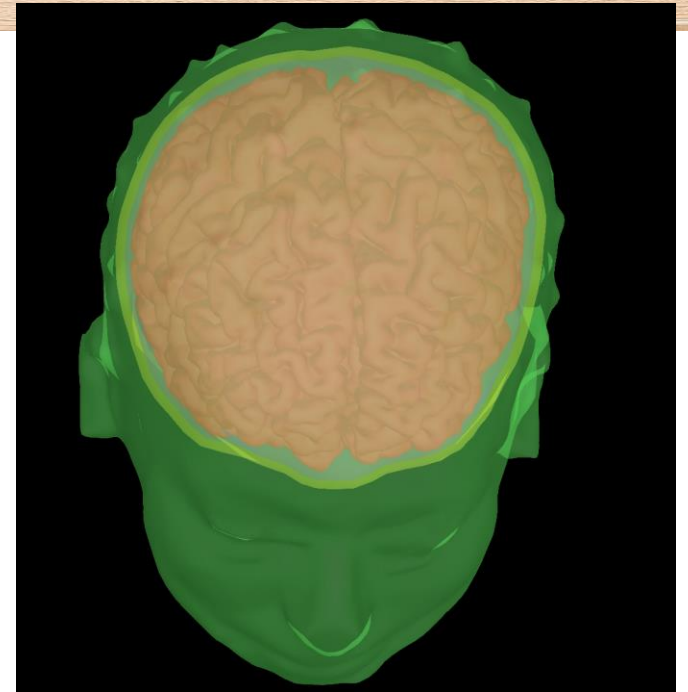
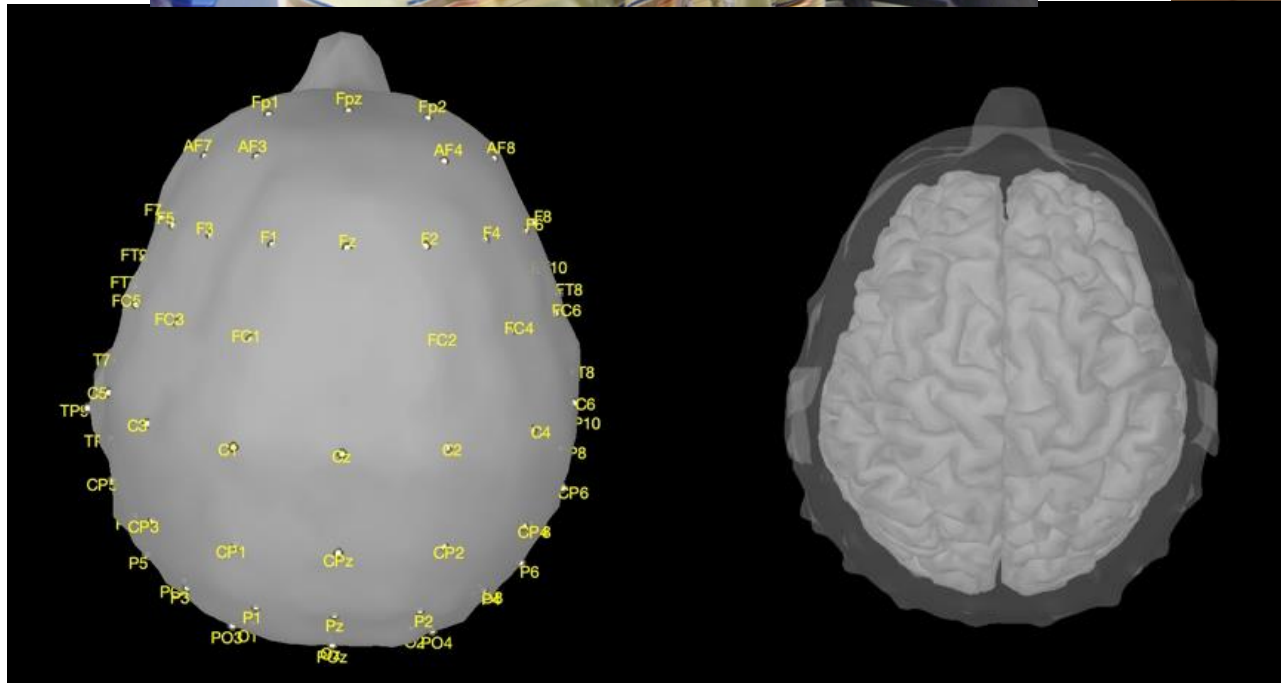
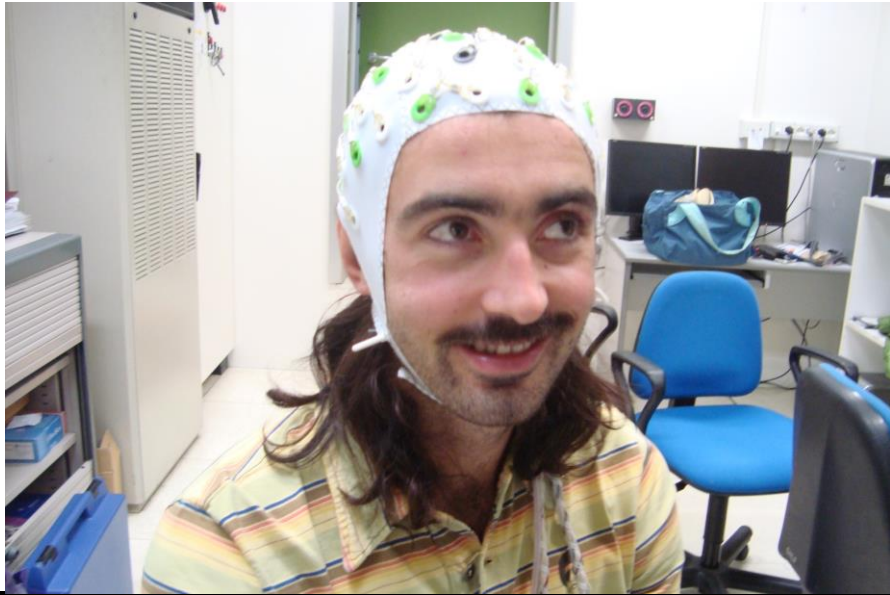"My drawing was not a picture of a hat.
It was a picture of a boa constrictor digesting an elephant."

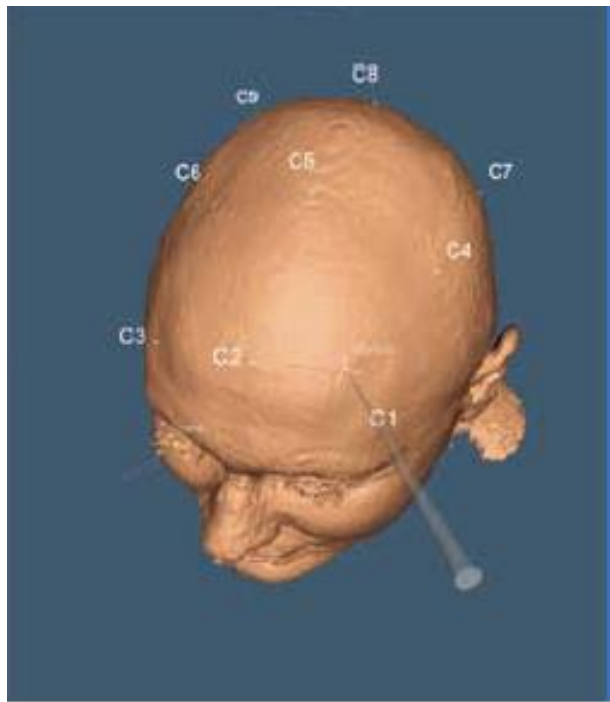
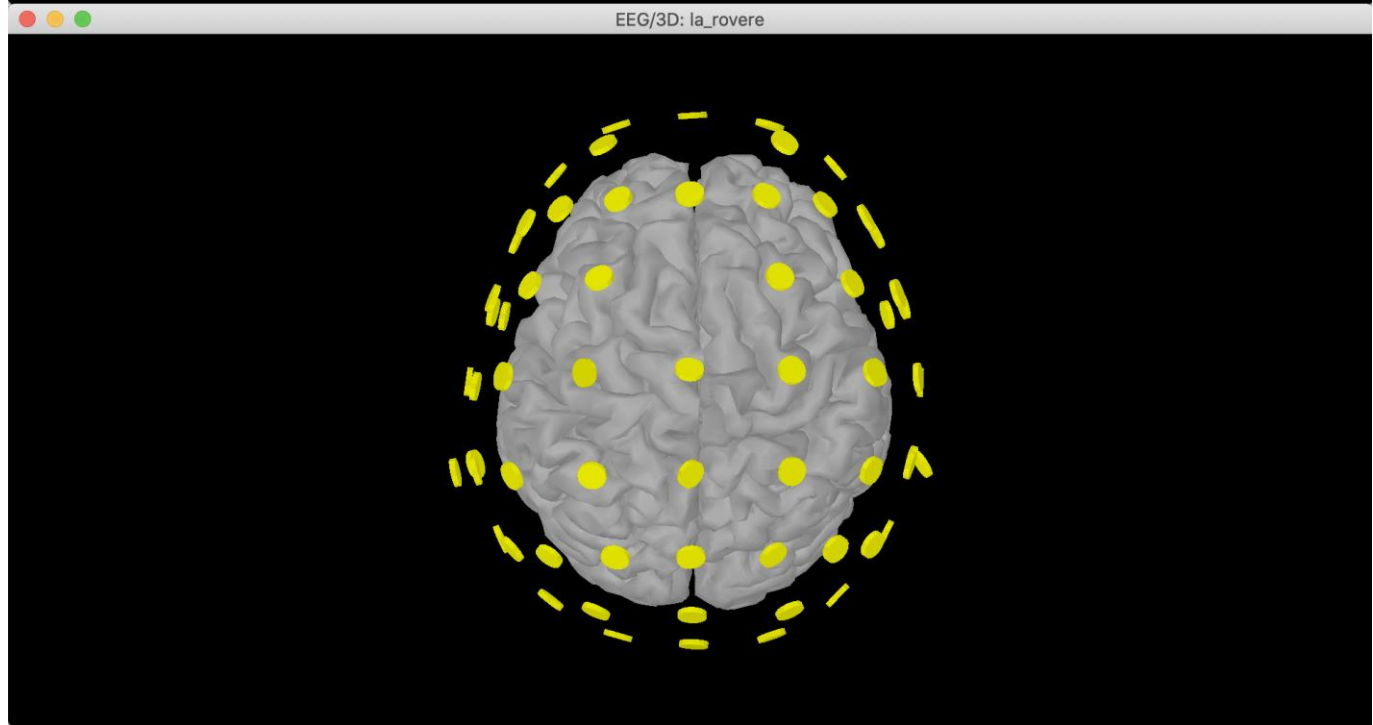
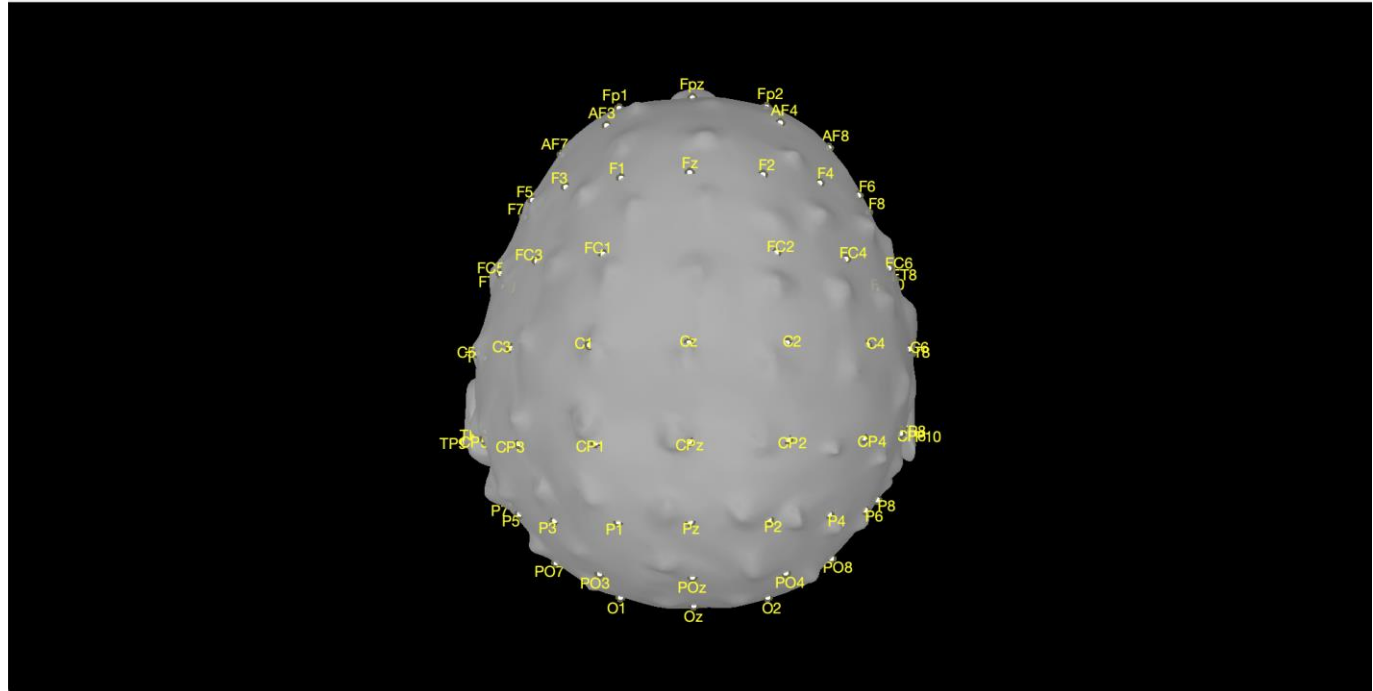


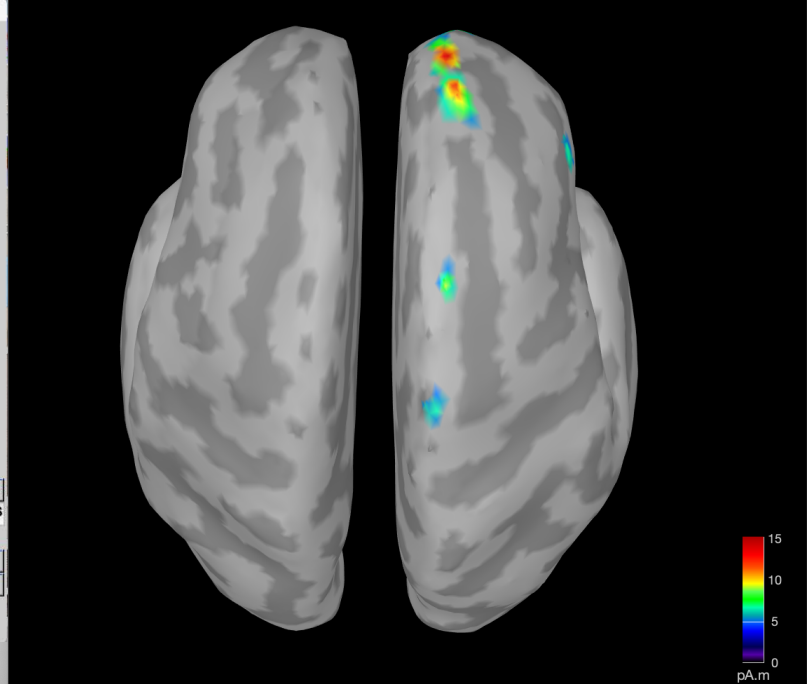
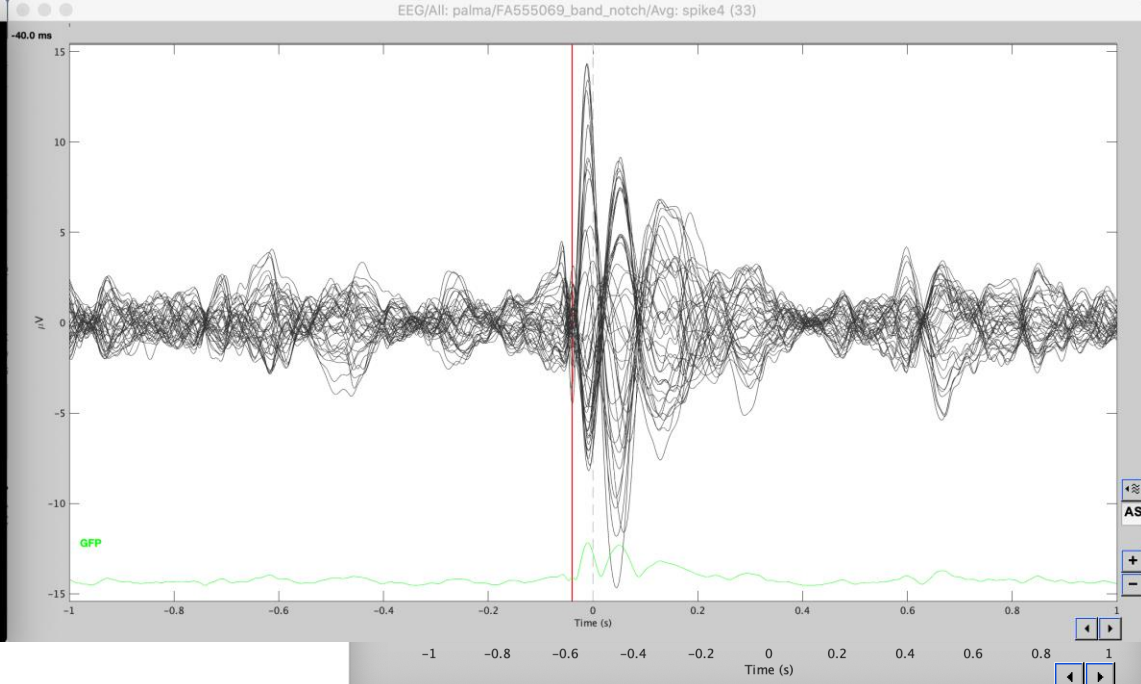
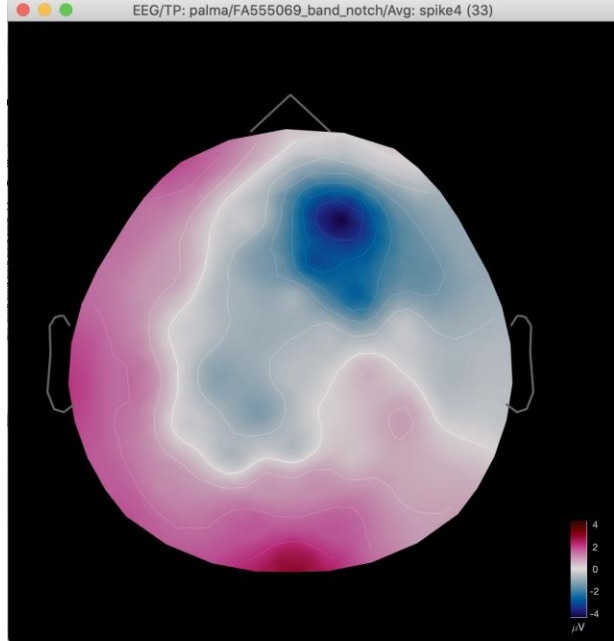
Electric Source Imaging: technical



HD-EEG Electric Source







EEG/MriViewer: palma/FA555069_band_notch/Avg: spike4 (33)/cMEM: : EEG(Full) | timewindow: -0.05 to 0.1s | smooth=0.6 2018 (DKT)

Coronal: y=172 Sagittal: x=150 Superior frontal R | value=70

Keyboard shortcuts:
 [Y] / [SHIFT]+[Y]
 [3] / [4]

Display options

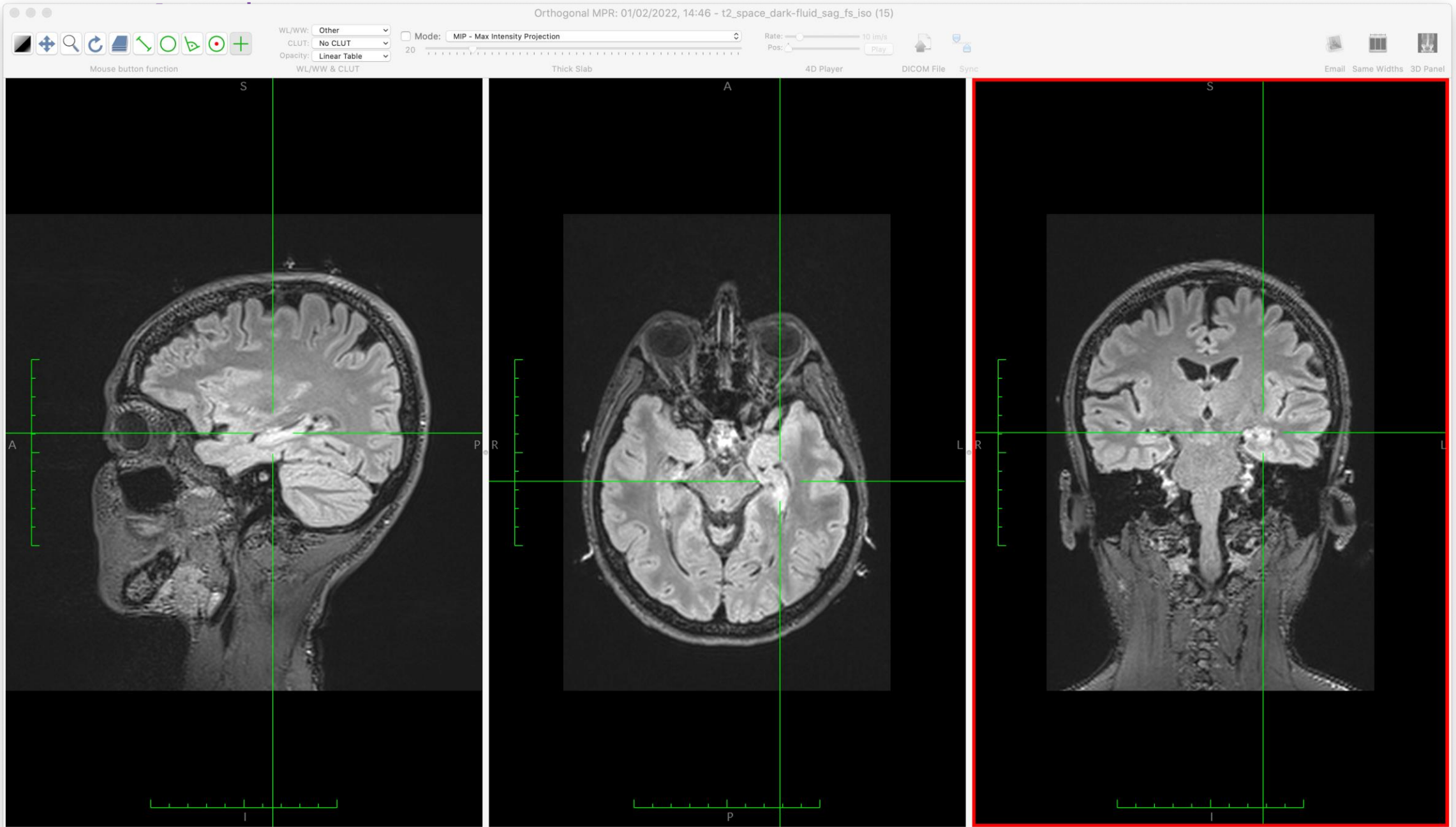
- MIP: Anatomy
- Crosshairs
- Neurological
- MIP: Functional
- Controls
- Radiological

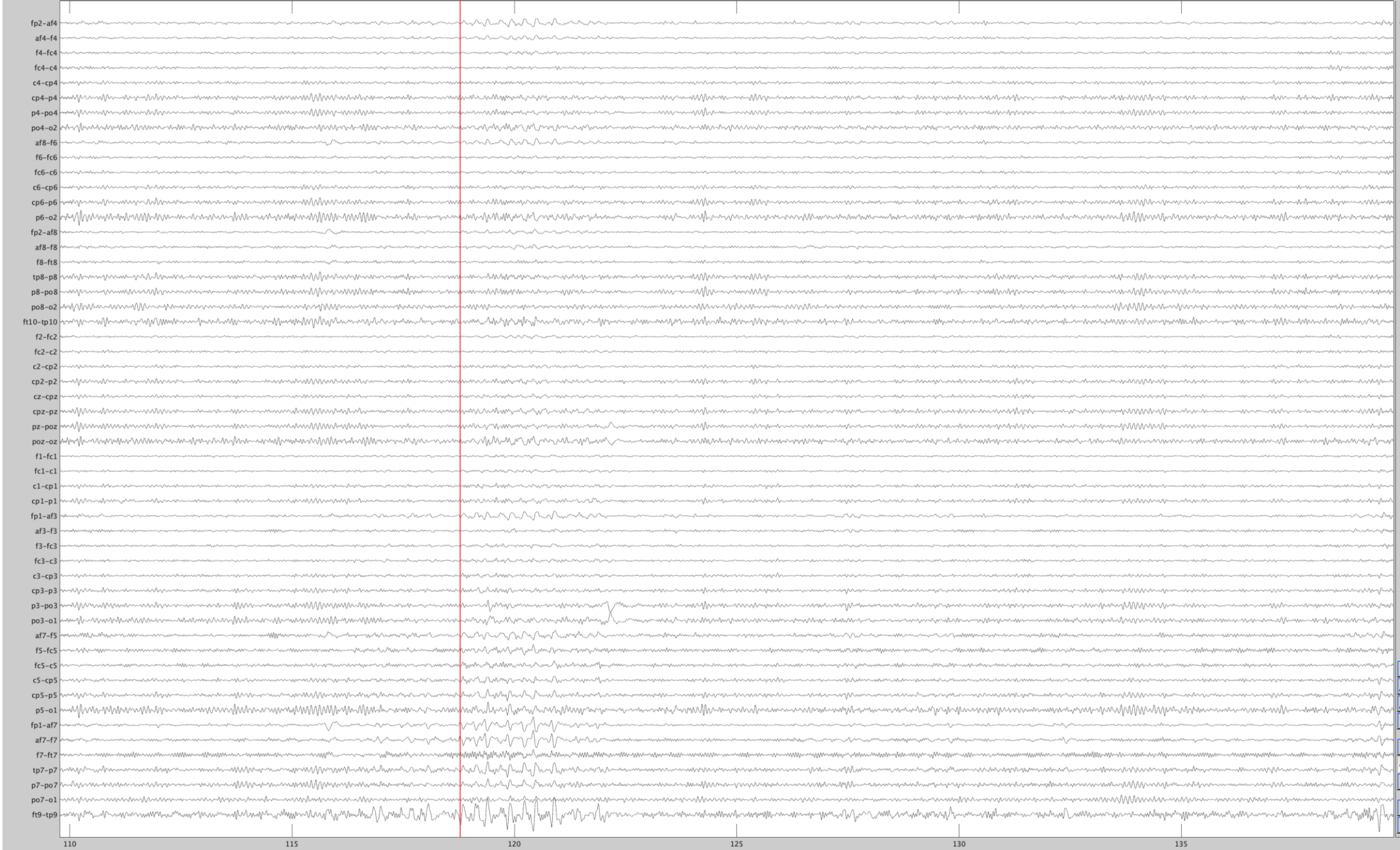
Coordinates (millimeters)

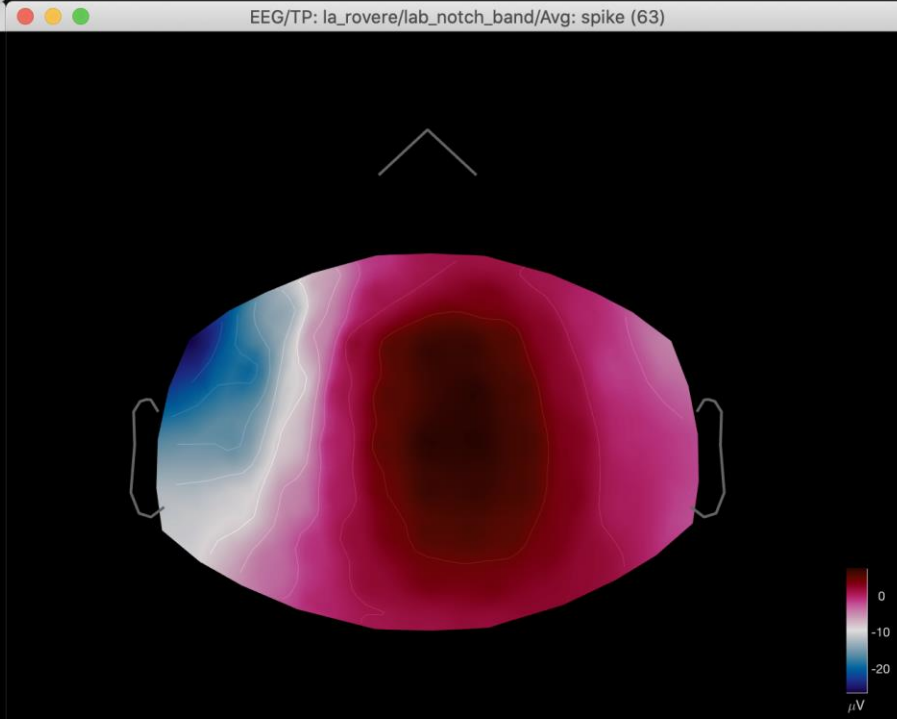
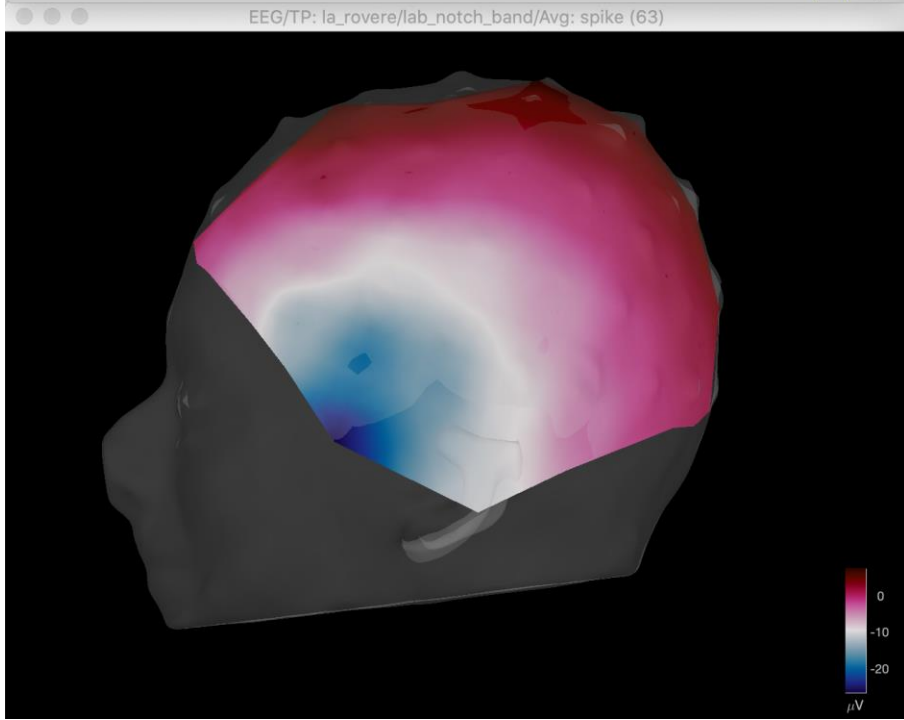
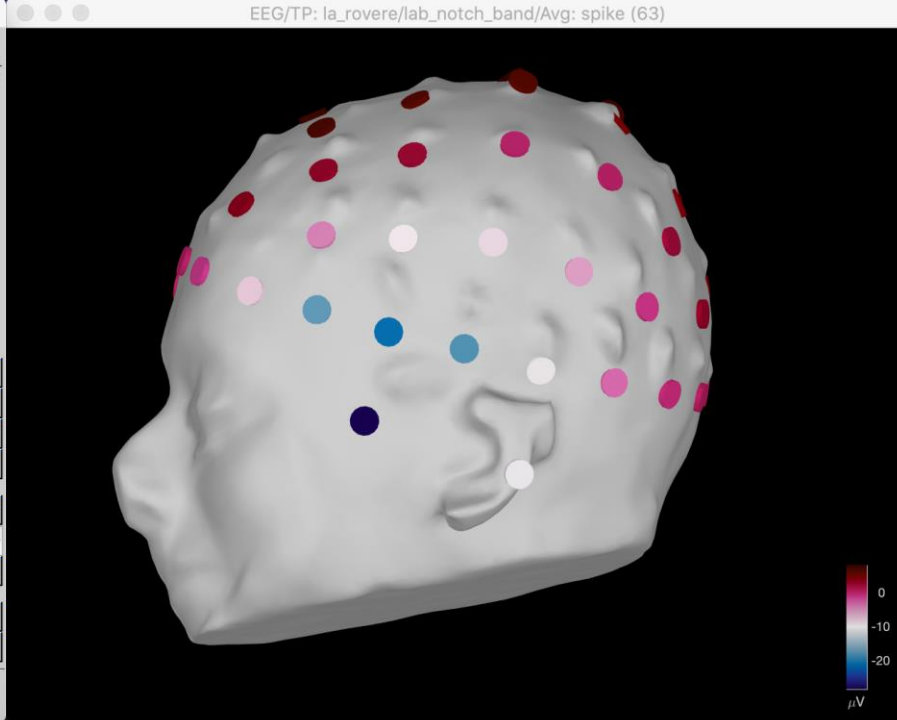
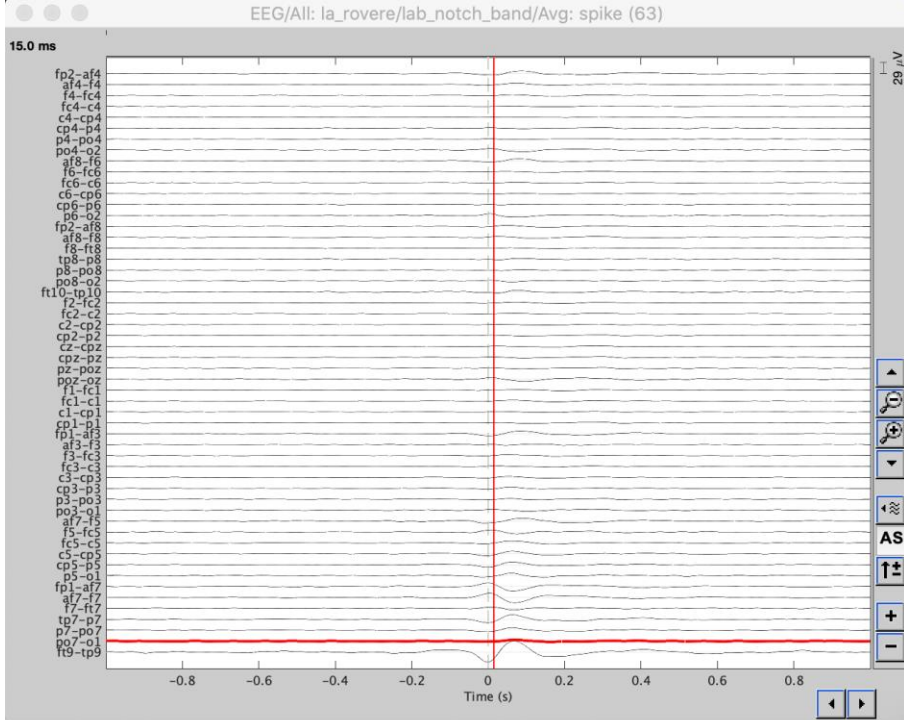
MRI:	x: 150.00	y: 172.00	z: 153.00
SCS:	x: 68.16	y: -24.45	z: 59.16
World:	x: 9.76	y: 26.76	z: 23.47
MNI:	Click here to compute MNI normalization		

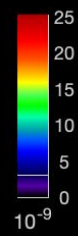
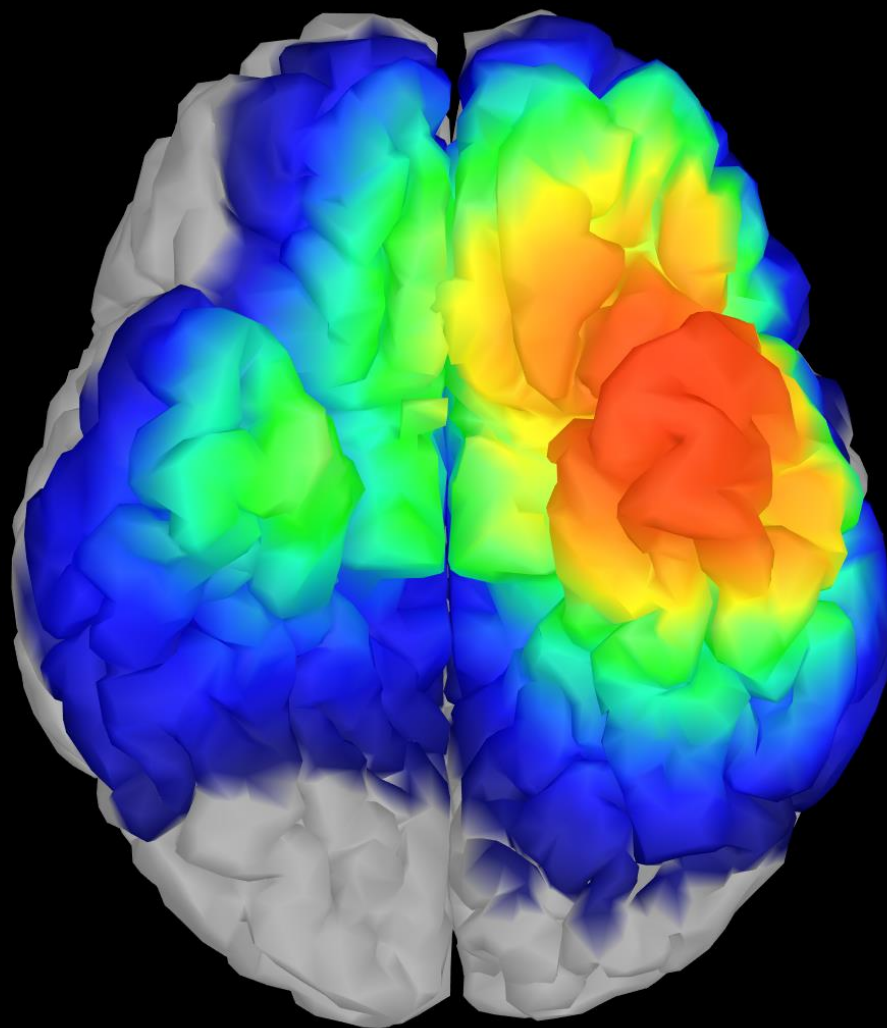
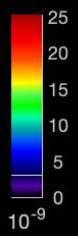
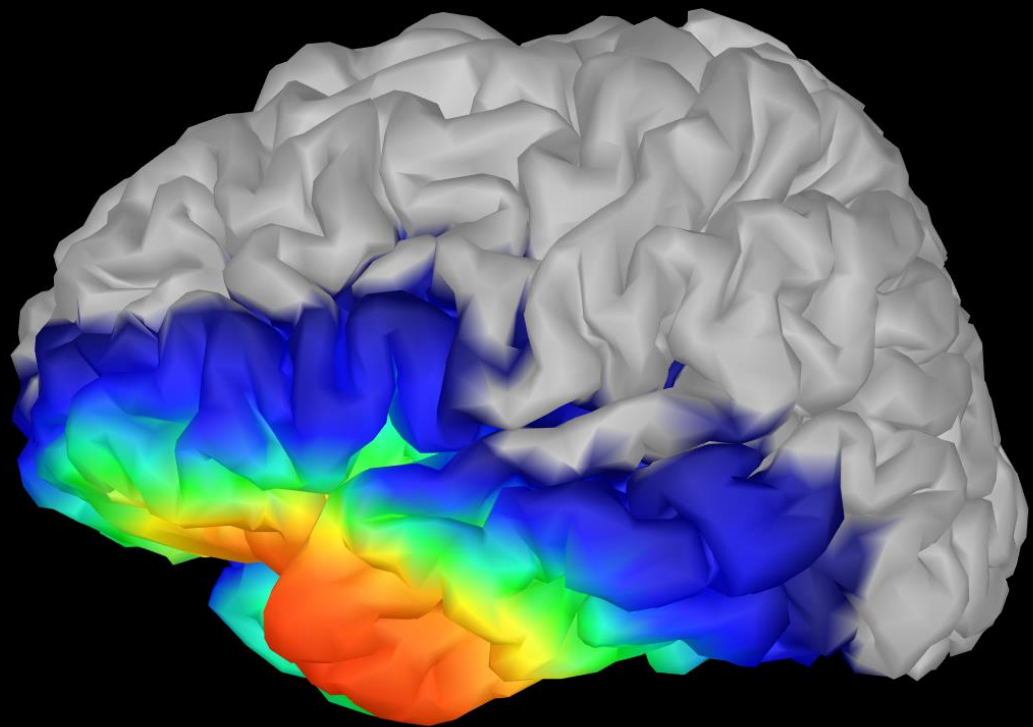
L. L. Donna 35 aa. Epilessia temporale sn

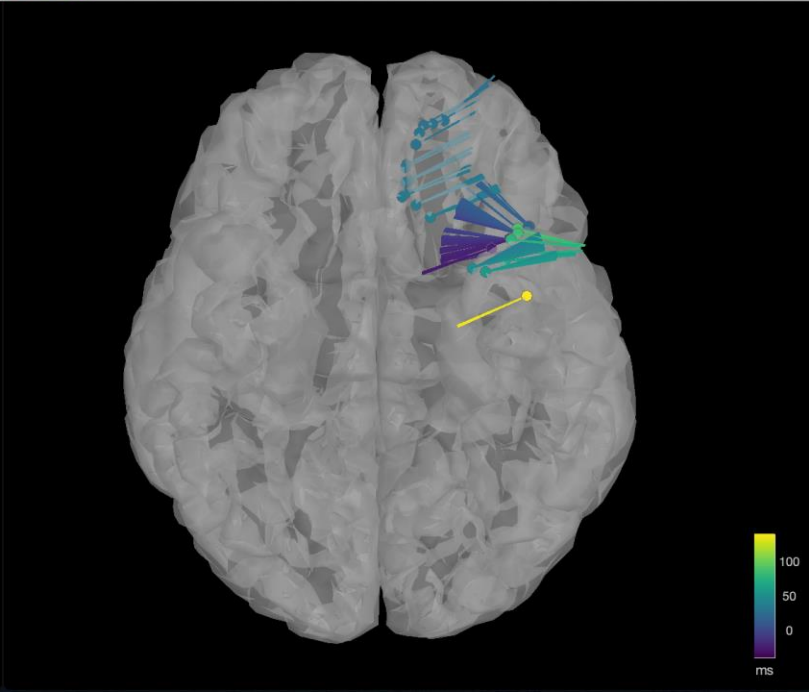
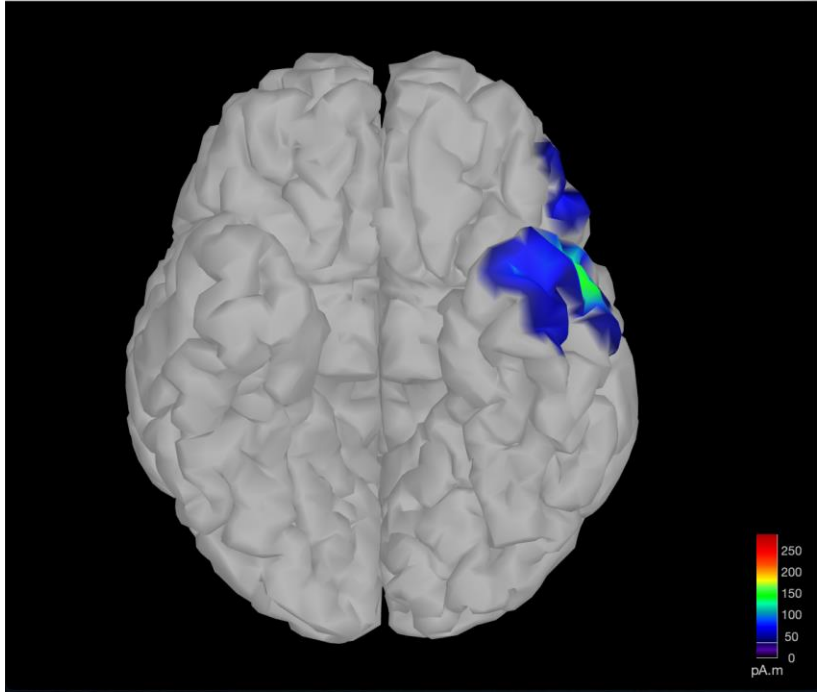
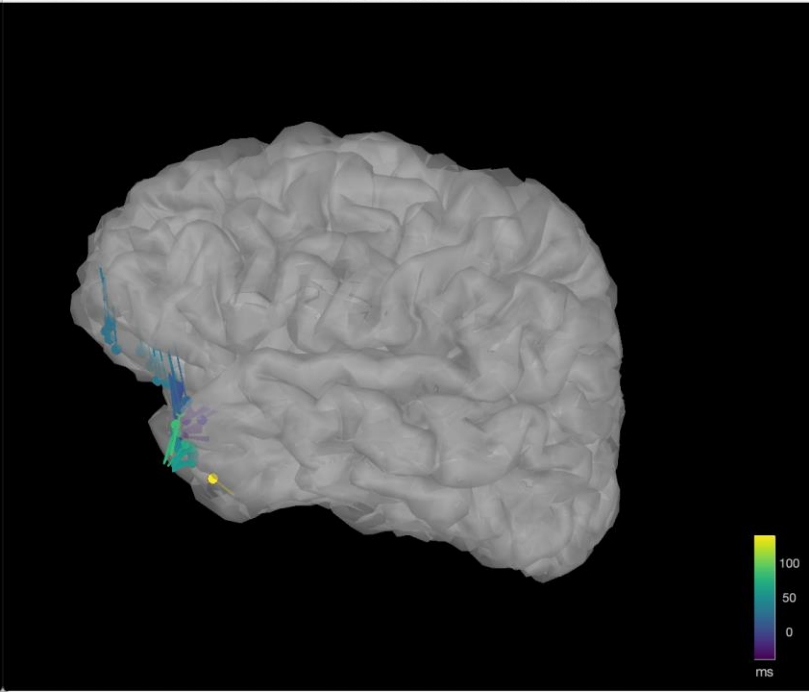
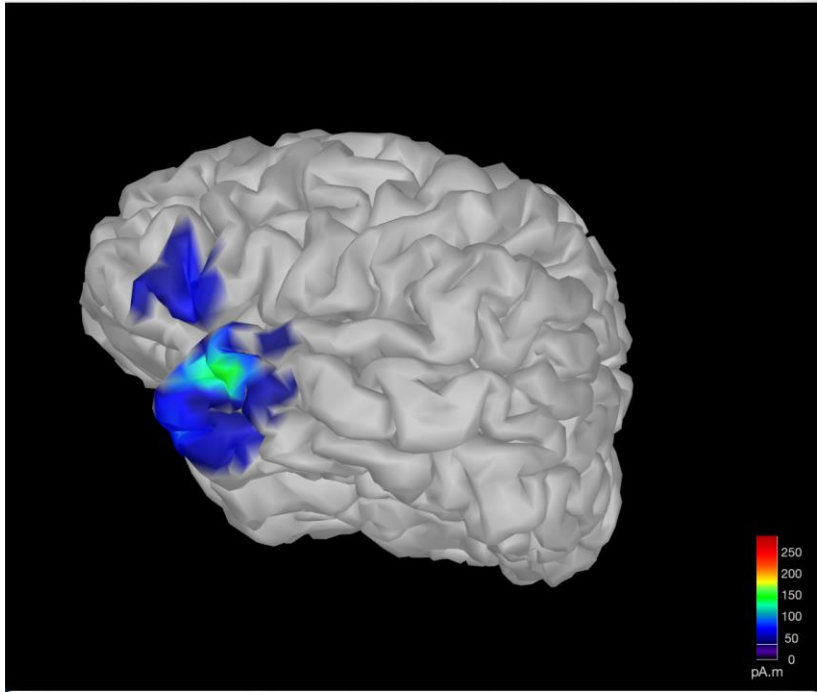
S


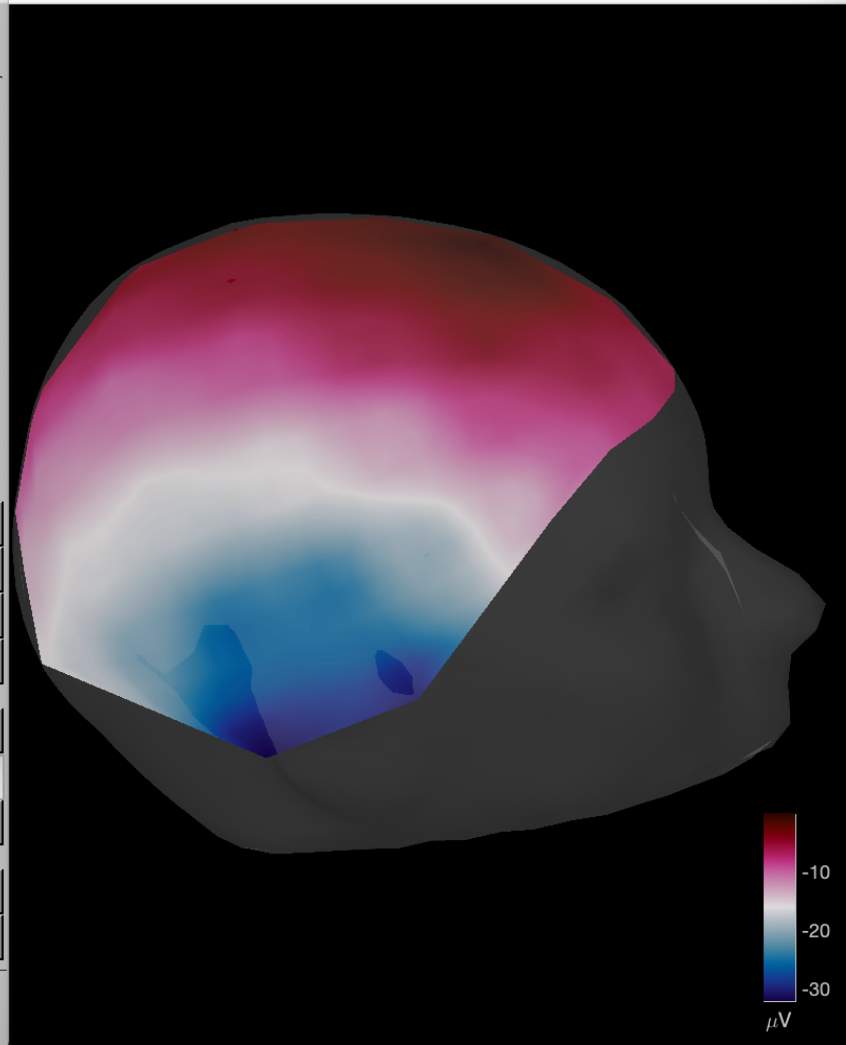
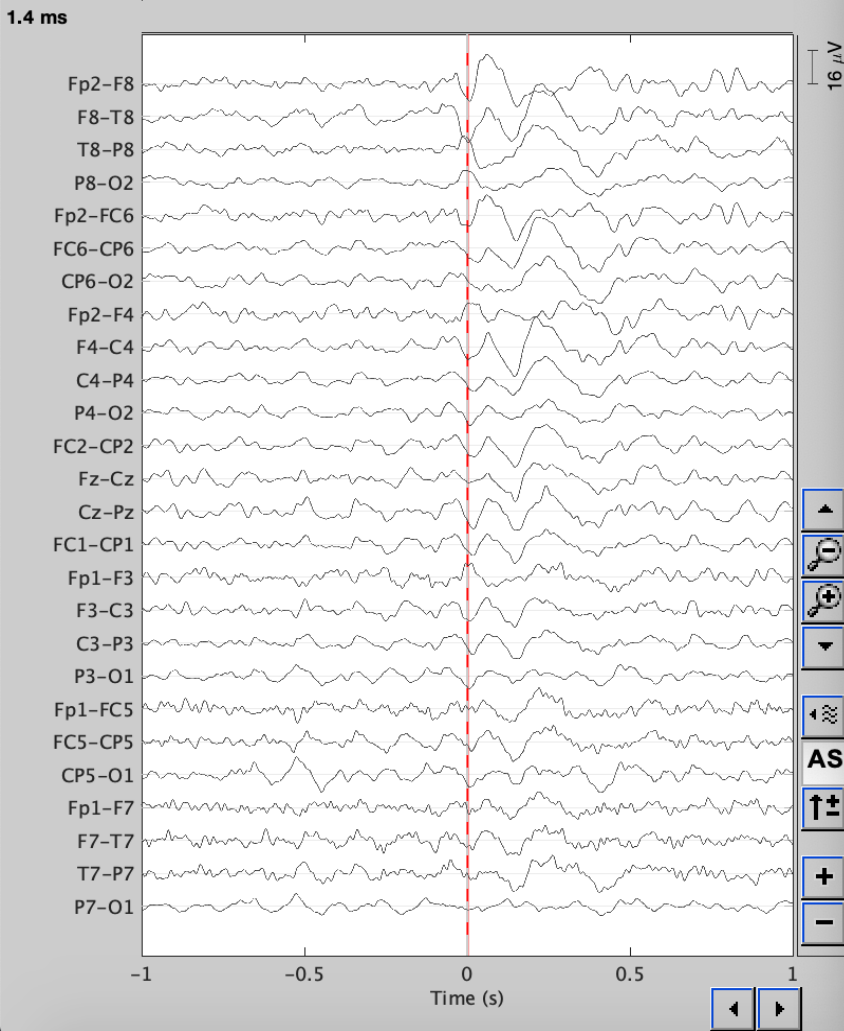




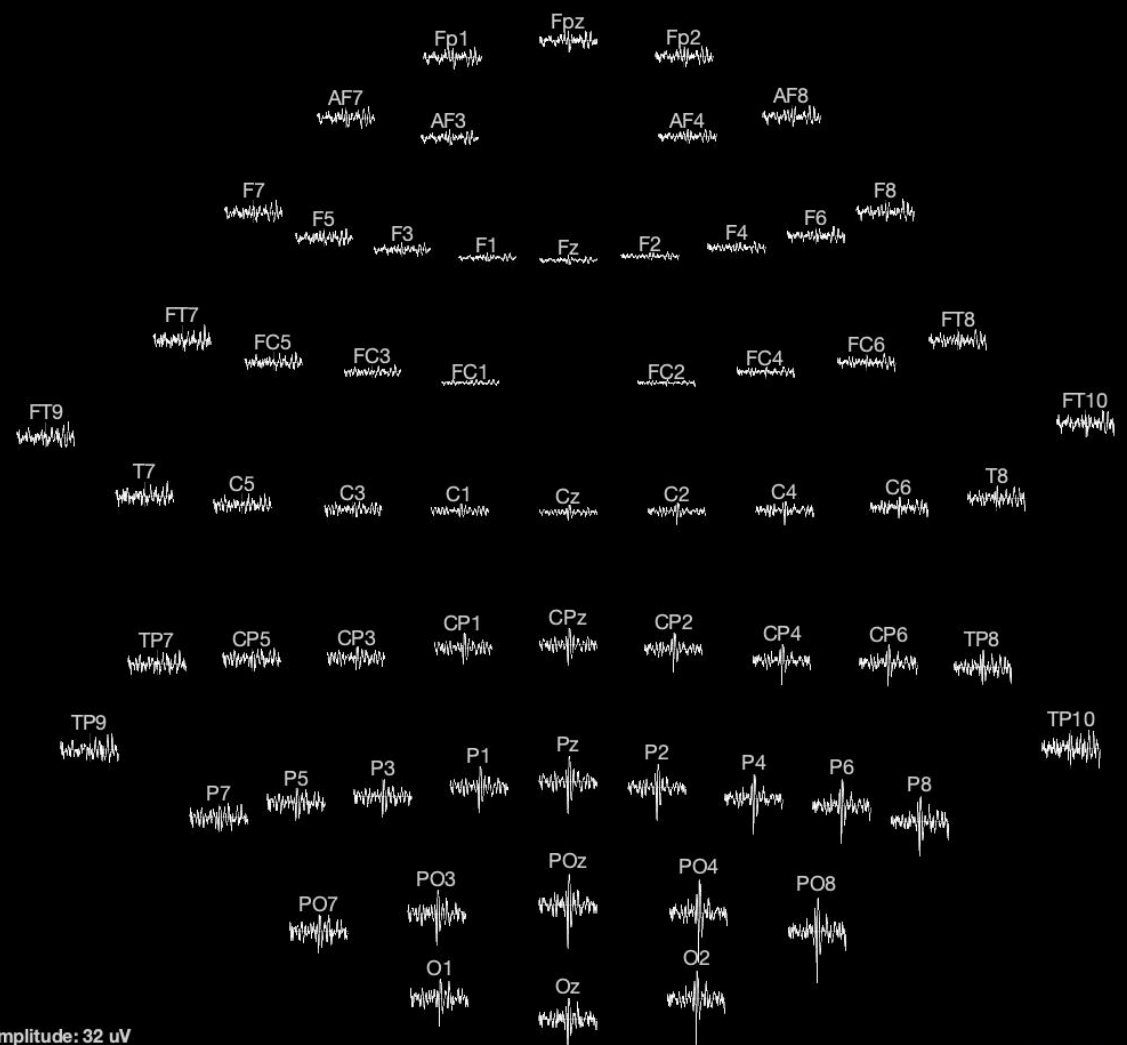


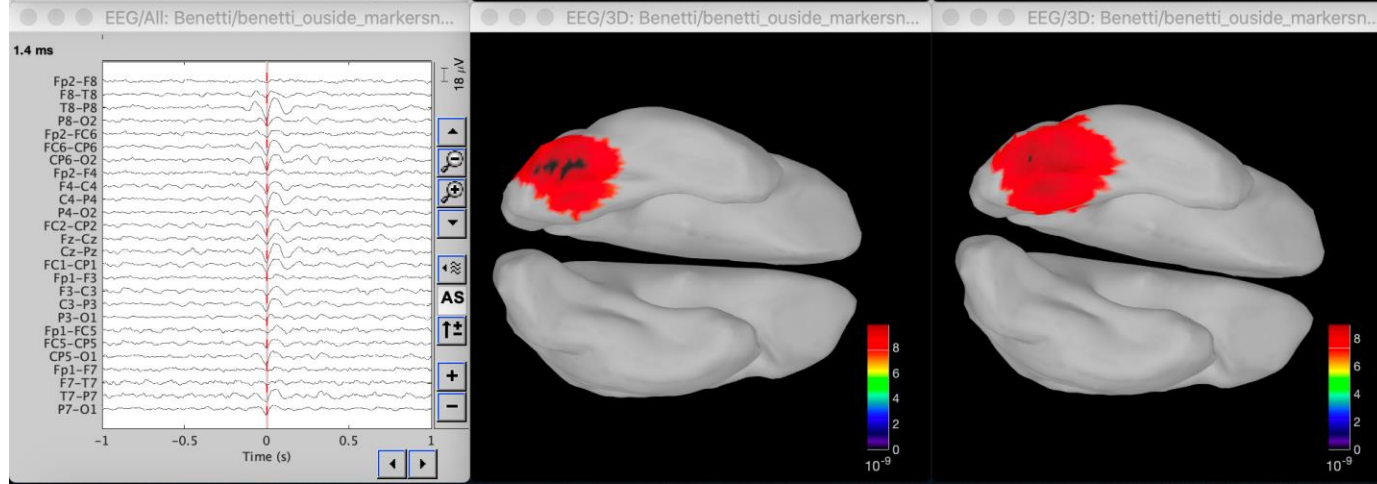
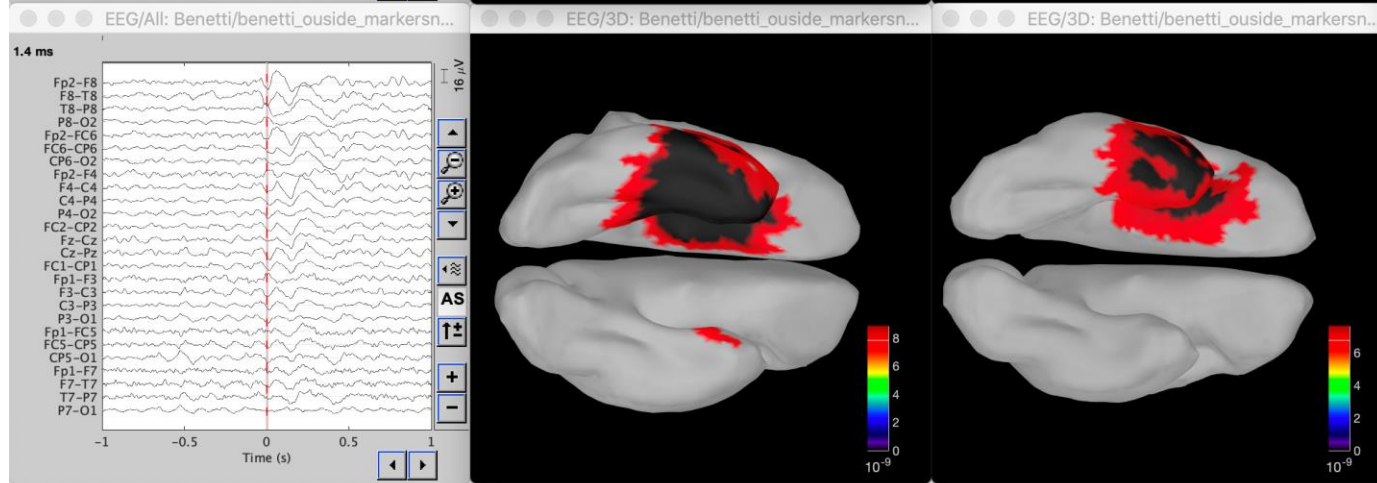
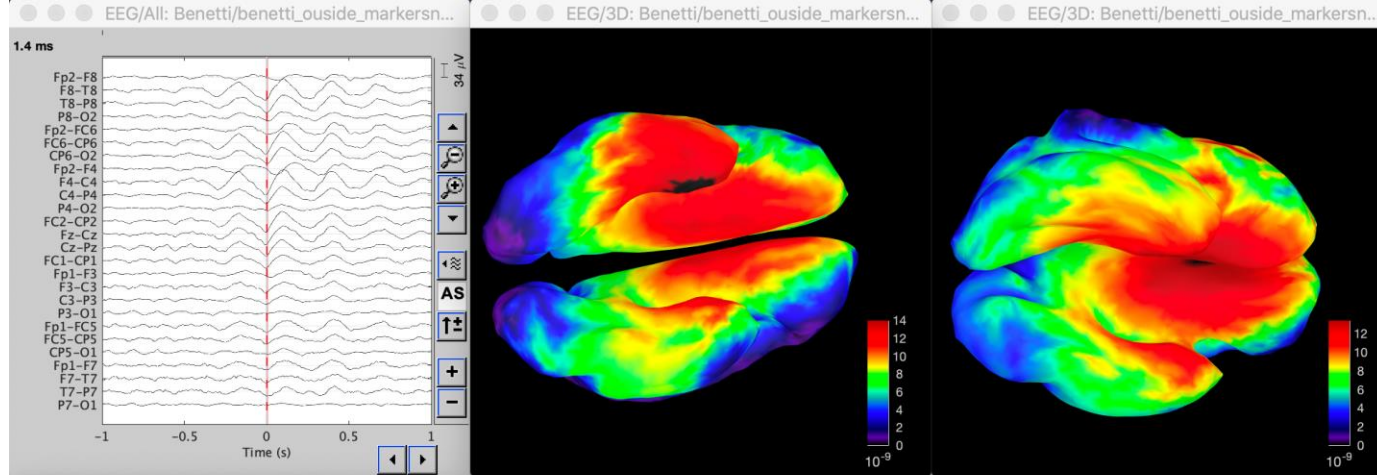


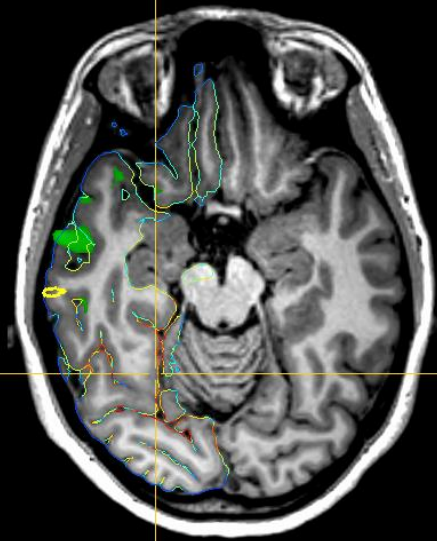




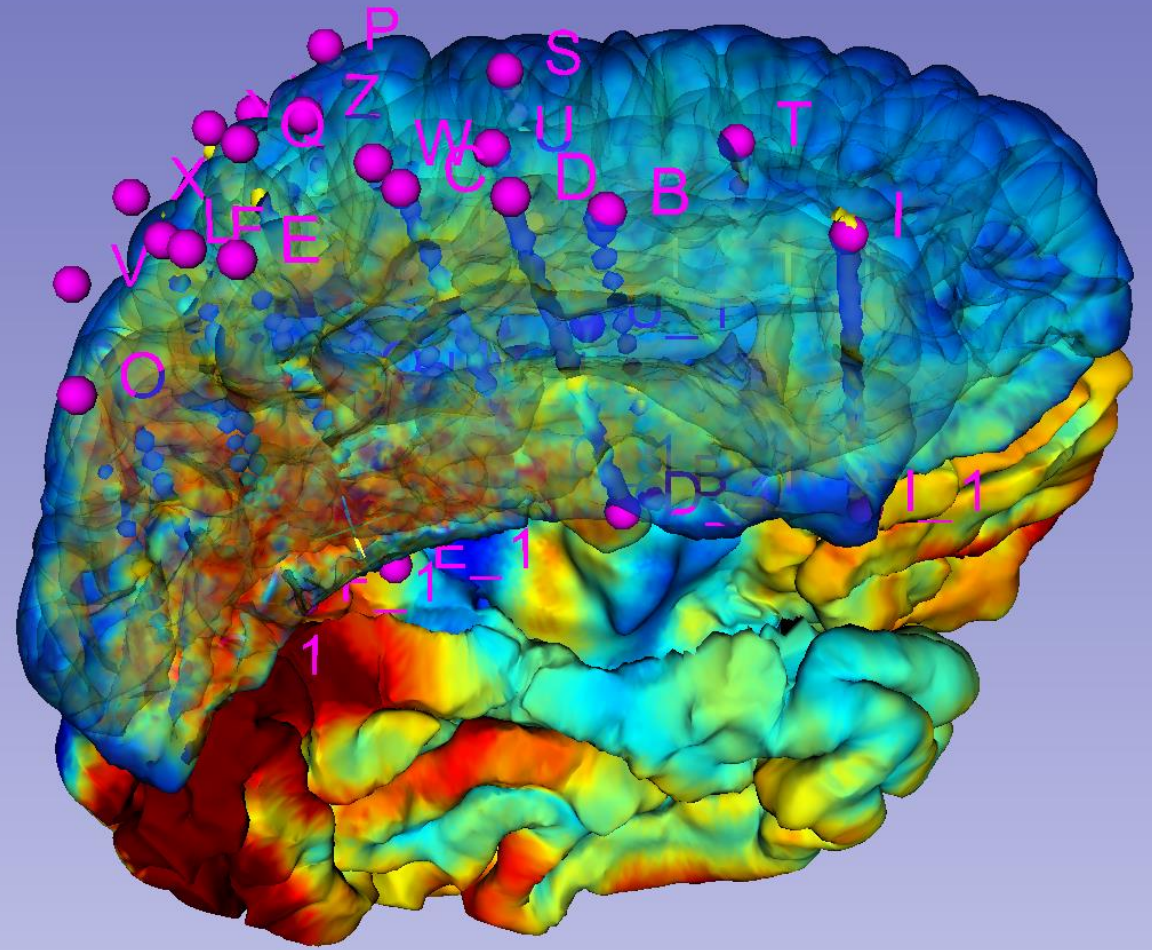






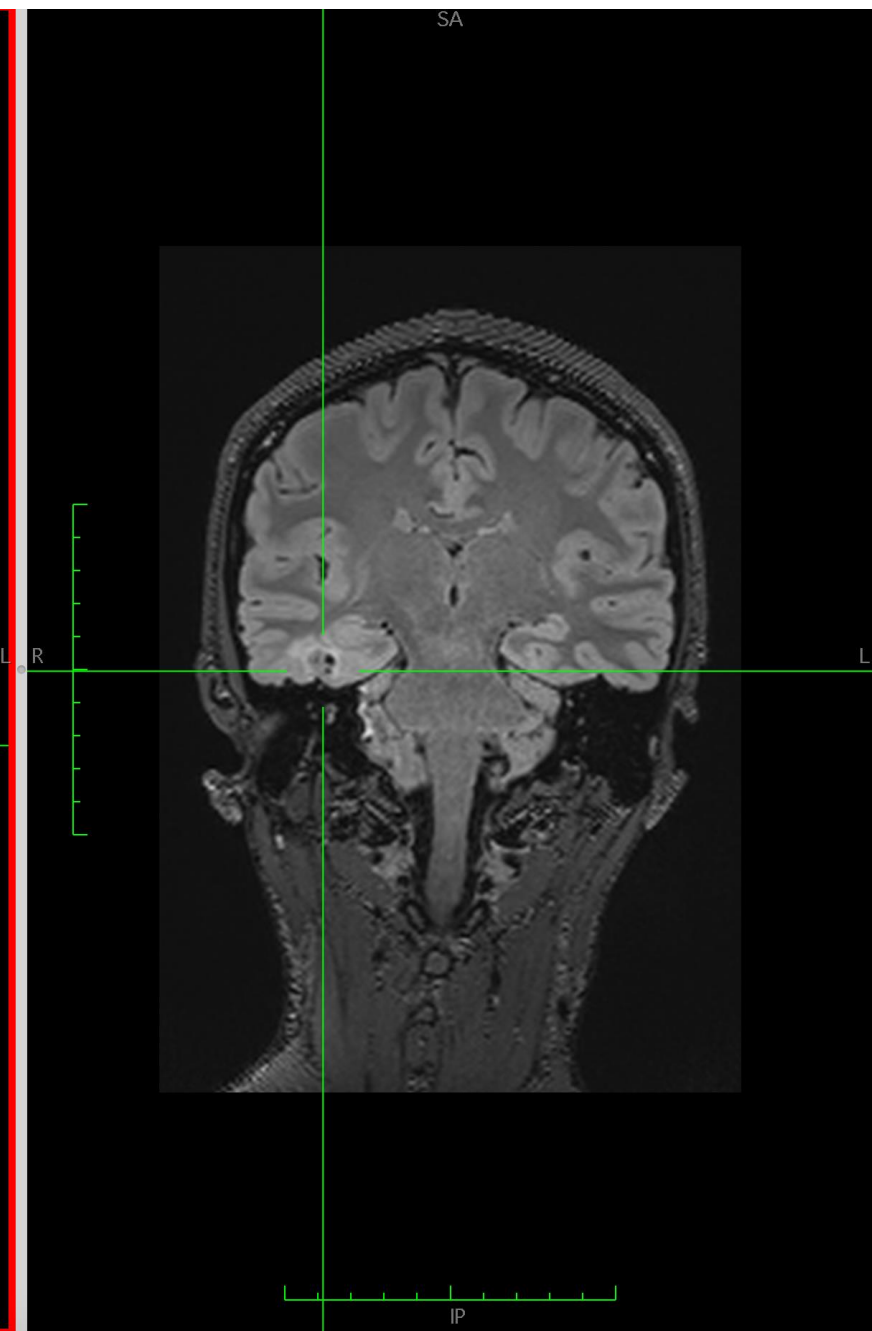
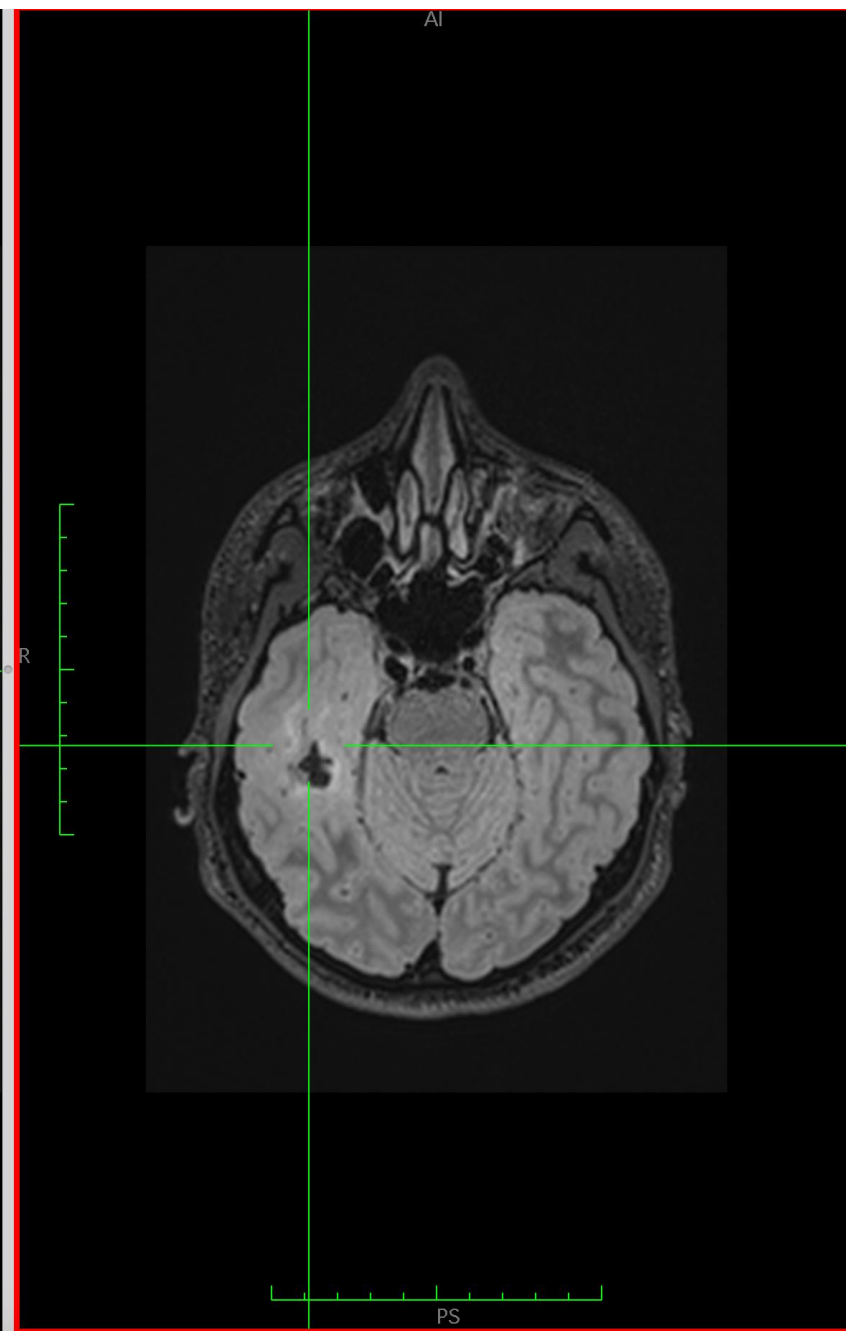
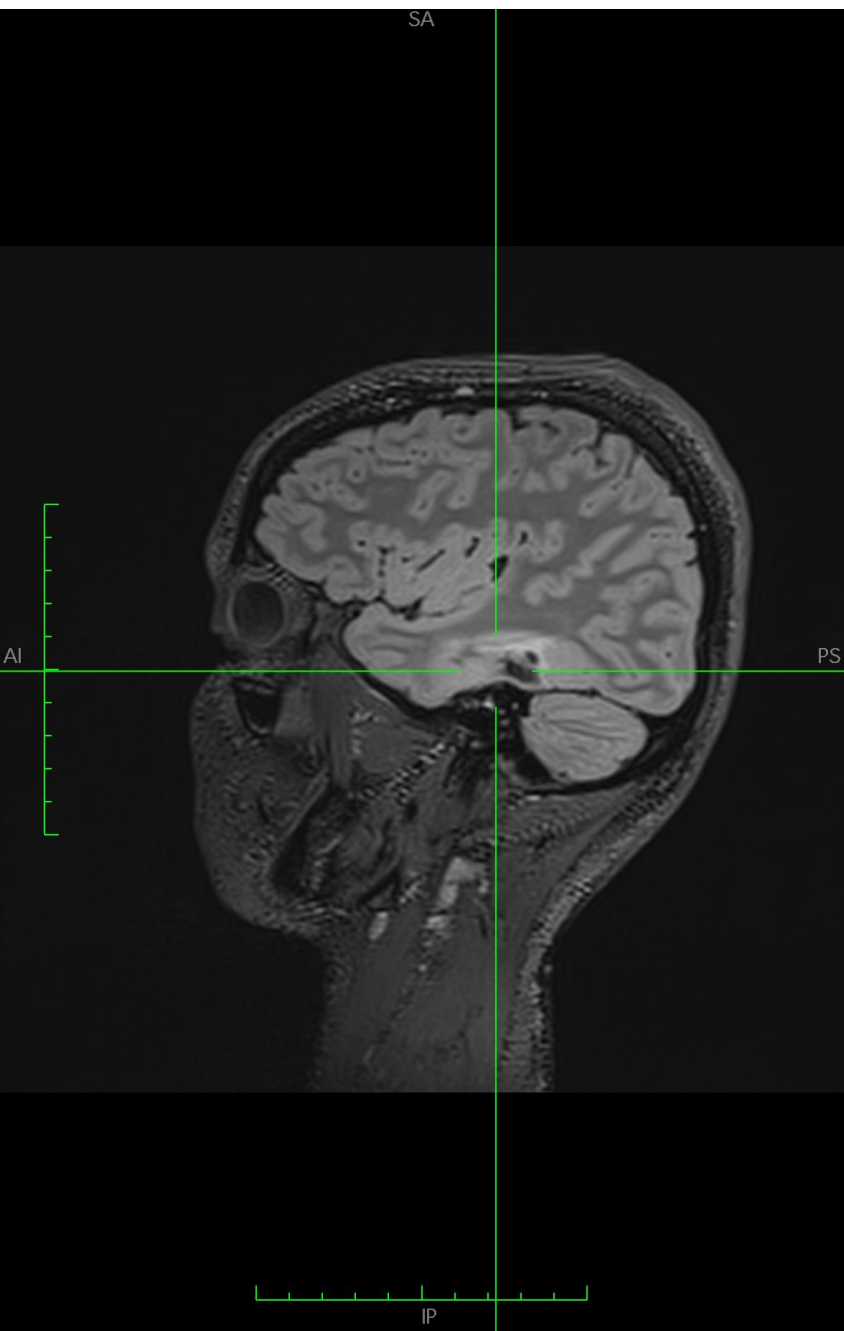


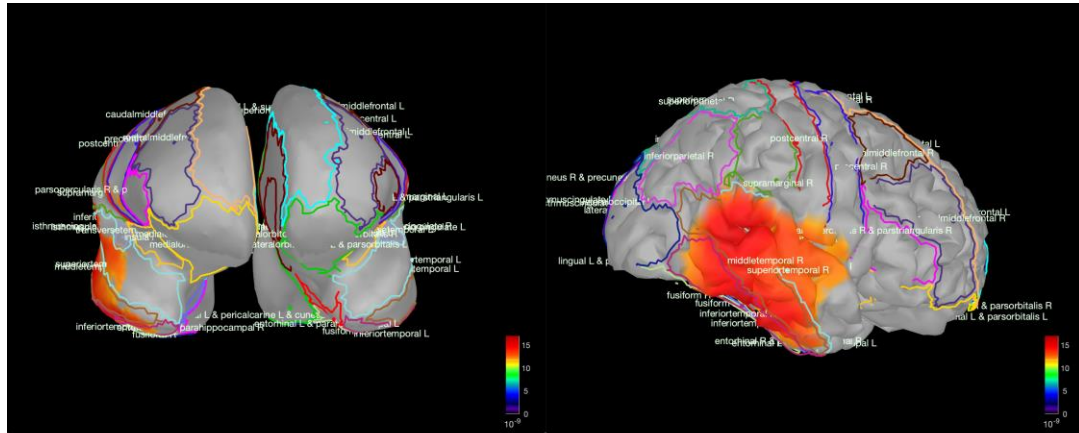
F: run1_spiketemporal_to_ref (90%)
B: ref



Electric source Imaging: Ricerca

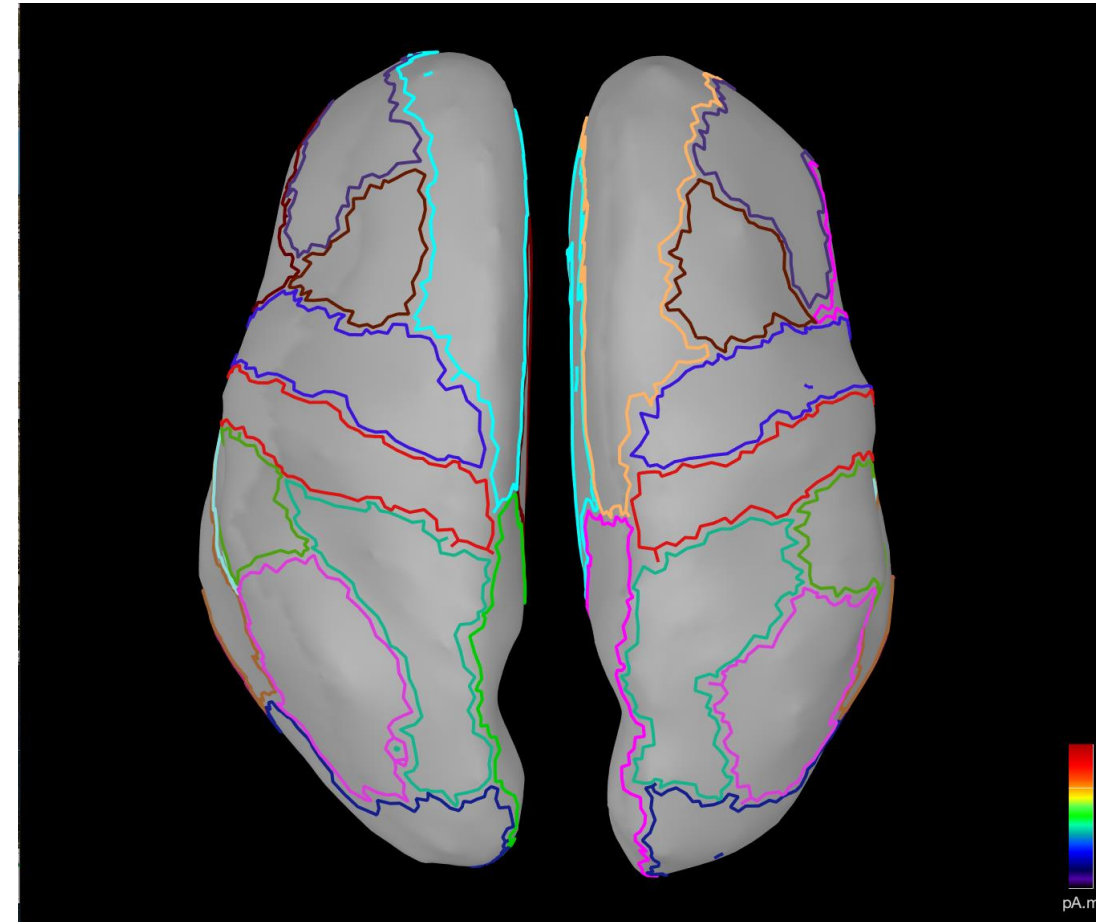
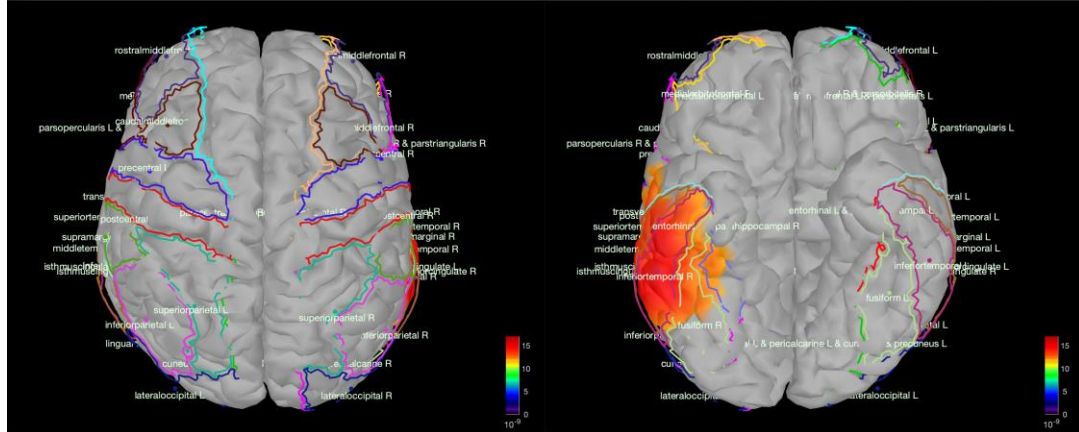
SEMEIOLOGIA CRISI	Crisi focali con alterazione della consapevolezza (alcuni elementi atipici)
EZIOLOGIA	Strutturale: tumore glioneuronale
EEG INTERCRITICO	Anomalie fronto-temporali destra > sinistra
RM 3 T	Alterazione del giro fusiforme (regione temporobasale e temporo-occipitale) con blurring del polo a destra
PET-FDG CEREBRALE	Ipfissazione temporo-mesiale destra (posteriore > anteriore)
RESEZIONE CHIRURGICA	Lobectomia temporale anteriore con lesionectomia
OUTCOME POST-CHIRURGICO	ILAE 1, ENGEL Ia



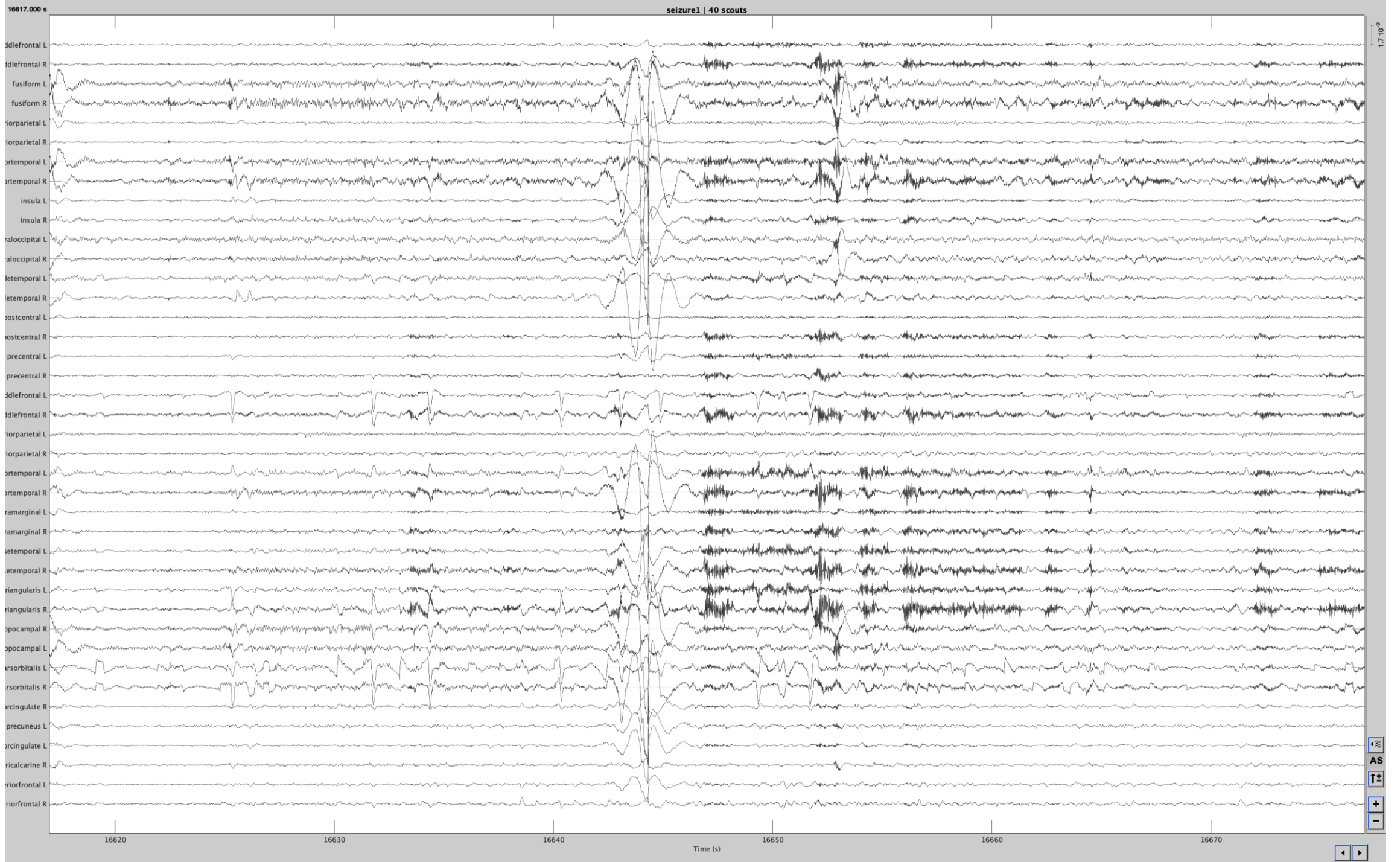


EEG/3D: Achim/UN003285_band_notch/Avg_spikes (130) (sLORETA; EEG(Unconstr)) 2018

EEG/3D: Achim/UN003285_band_notch/Avg_spikes (130) (sLORETA; EEG(Unconstr)) 2018

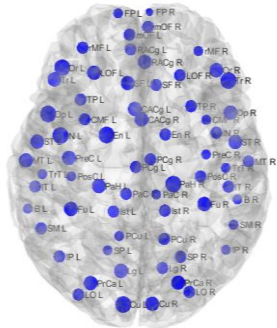


pA.m

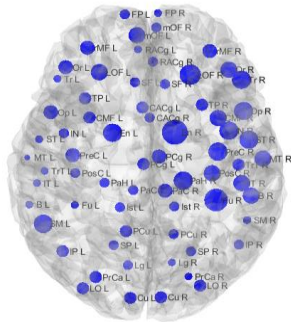


Temporal Granger Causality

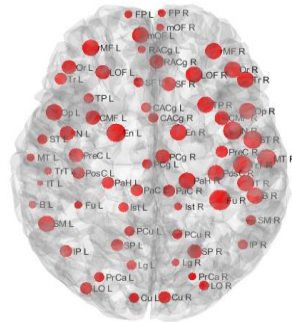
Preseizure: [-6 -1]



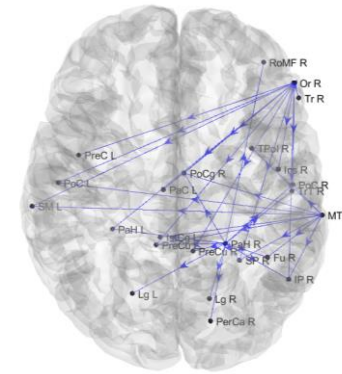
Preseizure: [-5 0]



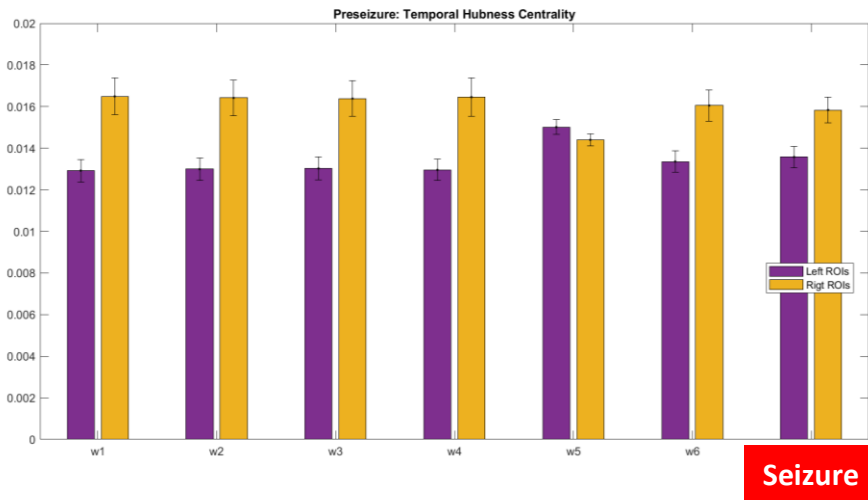
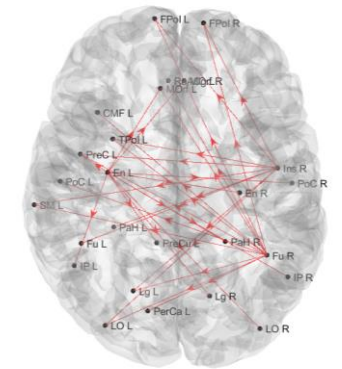
Seizure Onset: 0-5



Preseizure: Temporal Hubness Network



Seizure: Temporal Hubness Network



LATERALIZZAZIONE

PRE-SEIZURE:
 Middle Temporal R
 Parahippocampal R
 Parsorbitalis R

SEIZURE:
 Fusiform R
 Insula R
 Entorhinal L

LOCALIZZAZIONE
 (all'interno dell'area resecata)



THE IMPLEMENTATION OF ELECTRIC SOURCE IMAGING AND EEG/fMRI IN PRESURGICAL EVALUATION OF DRUG-RESISTANT EPILEPSY

PhD Student Lorenzo Ferri

Tutor: Prof Paolo Tinuper

Co-tutor: Prof.ssa Francesca Bisulli

XVI Ciclo di Dottorato in Scienze Biomediche,

