Risultati dello studio GISMa sulla concordanza diagnostica nei referti istologici da prelievi con microbiopsia percutanea

Maria Grazia Cattani

U. O. Anatomia Patologica

Ospedale Bellaria, Dipartimento Oncologico

Azienda USL Bologna

CONCORDANZA DIAGNOSTICA NELLE AGOBIOPSIE

CONVEGNO NAZIONALE GISMa,
Ottobre 2007

Simonetta Bianchi Dipartimento Patologia Umana ed Oncologia
AOU Careggi Firenze
Mariagrazia Cattani UO Anatomia Patologica Ospedale Maggiore Bologna
Mauro Biancalani UO Anatomia Patologica Empoli

Patologi Emilia Romagna
Patologi Piemonte
Patologi Toscana

Saverio Caini UO Epidemiologia molecolare e nutrizionale CSPO Firenze
Domenico Palli UO Epidemiologia molecolare e nutrizionale CSPO Firenze

Studio di concordanza diagnostica su core biopsy

Lo studio, partito a gennaio 2006 e conclusosi nell'ottobre 2007, ha visto la partecipazione di **31 centri**:

7 della regione Emilia Romagna (Ospedale Maggiore e Ospedale Bellaria di Bologna, Ospedali di Reggio Emilia, Forli', Modena, Cesena e Rimini),

1 del Veneto (Castelfranco Veneto),

14 centri della regione Toscana

9 centri della regione Piemonte.

scopo dello studio

Valutare la **concordanza diagnostica** nelle core biopsy preoperatorie utilizzando le categorie diagnostiche B1-B5 proposte dalle Linee Guida Inglesi (NHSBSP 2005).

BREAST SCREENING WIDE BORE NEEDLE BIOPSY FORM

Surname _____ Forenames _____ Date of birth _____

NHS no. _____ Screening no. _____ Hospital no. _____

Centre _____ Report no. _____

Side ☐ Right ☐ Left Number of cores _____

Calcification present on specimen x-ray? ☐ Yes ☐ No ☐ Radiograph not seen

Histological calcification ☐ Absent ☐ Benign ☐ Malignant ☐ Both

Localisation technique ☐ Palpation ☐ X-ray guided ☐ Ultrasound guided ☐ Stereotactic

Opinion

☐ B1. Unsatisfactory/Normal tissue only

☐ B2. Benign

☐ B3. Lesion of uncertain malignant potential

☐ B4. Suspicion of malignancy

☐ B5. Malignant

a. ☐ In-situ

b. ☐ Invasive

c. ☐ Not assessable

PATHOLOGIST _____ Operator taking biopsy _____

Date _____

Comment _____

Figure 8 Example of a WBN reporting form.

Particolare attenzione e' stata rivolta alla **categoria diagnostica B3** (lesioni ad incerto potenziale di malignita') dato che proprio in queste lesioni e' piu' accentuata la variabilita' interosservatore e quindi ridotta la riproducibilita' diagnostica.

Modalita' studio

50 vetrini

- Selezionati dai patologi coordinatori
- Scheda preformata con categorie diagnostiche da B1 a B5
- B3: 5 sottogruppi diagnostici
- Risultati valutati statisticamente
- Riproducibilita' individuale e per gruppo regionale in termini di sensibilita' e specificita' confontando il kappa statistico come misura di concordanza fra osservatori

Variabilita' inter ed intraosservatore

Rosai J.

Borderline epithelial lesions of the breast. Am J Surg Pathol 15: 209-211, 1991.

Elston CW et al. Causes of inconsistency in diagnosing and classifying intraductal proliferations of the breast. European Commission Working Group on Breast Screening Pathology.

Eur J Cancer 36: 1769-17772, 2000.

Classificazioni di riferimento

- NHSBSP for Pathology Reporting in Breast Disease, N° 58, 2005

- WHO Classification of Tumours. FATavassoli and P Devilee. Pathology and Genetics of Tumours of the Breast and Female Genital Organs. IARC Press Lyon, 2003

- Schnitt SJ, Vincent-Salomon A. Columnar cell lesions of the breast. Advances in Anatomic Pathology 10: 113-124, 2003.

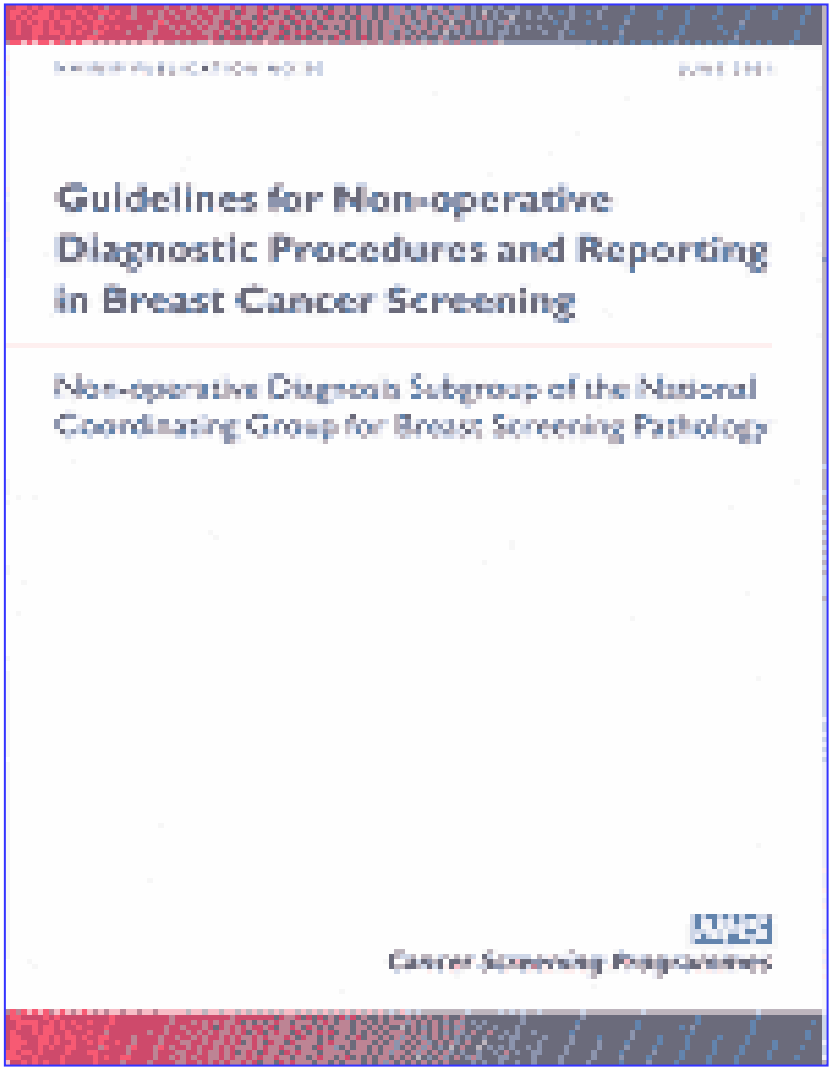

NHSBSP Guidelines for Pathology Reporting in Breast Disease, N° 58, 2005

Dr I O Ellis

Dr S Humphreys

Dr M Michell

Dr S E Pinder

Dr C A Wells

Dr H D Zakhour

Ian.Ellis@nottingham.ac.uk

World Health Organization Classification of Tumours

Pathology & Genetics

Tumours of the Breast and Female Genital Organs

Edited by Fattaneh A. Tavassoli & Peter Devilee

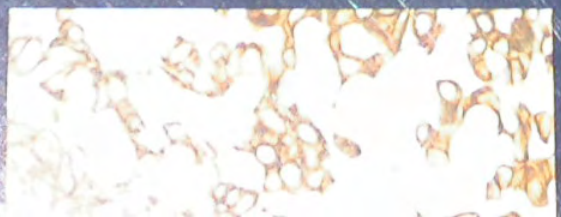

“Punto di partenza” dello studio

Necessita’ di approfondimento e confronto tra patologi sulla categoria B3

B3
(lesioni ad incerto potenziale di malignita')

- **IPERPLASIA DUTTALE ATIPICA**
- **NEOPLASIA LOBULARE (ALH E CLIS)**
- **RADIAL SCAR/ LESIONI SCLEROSANTI COMPLESSE**
- **LESIONI PAPILLARI**
- **LESIONI FIBROEPITELIALI**
- LESIONI MUCOCELE-LIKE

Jacobs, Timothy W. M.D.; Connolly, James L. M.D.; Schnitt, Stuart J. M.D.

Nonmalignant Lesions in Breast Core Needle Biopsies: To Excise or Not to Excise?

The American Journal of Surgical Pathology: Volume 26(9) September 2002 pp 1095-1110

ORIGINAL ARTICLE

Will the spectrum of lesions prompting a "B3" breast core biopsy increase the benign biopsy rate?

P J Carder, J C Liston

J Clin Pathol 2003;56:133–138

Aim: To audit the benign surgical biopsies in women screened, assessed, and referred by the Leeds/Wakefield Breast Screening Unit for the year 1999–2000 with a view to determining any association with a preoperative B3 core biopsy categorisation.

Methods: The results of all preoperative diagnostic procedures in all patients who underwent surgical excision for a lesion proving benign in the year 1999–2000 were reviewed. Cases were categorised according to whether the preoperative fine needle aspirate cytology (FNAC) or core biopsy had been equivocal or of uncertain malignant potential (C3/B3), inadequate or unrepresentative (C1/B1), or benign (C2/B2). In those cases with a C3/B3 FNAC or core biopsy result, reasons for the uncertainty were determined by examination of the report and, where necessary, slides. In cases with C1/B1 or C2/B2 investigations and in those without a preoperative procedure, the reasons for surgical referral were determined from the screening records. Case records of all patients with a B3 core biopsy categorisation who subsequently proved to have malignancy were also reviewed.

Results: Thirty six women had benign surgical biopsies in the 1999–2000 screening year. In 13 of the 36 patients, referral for diagnostic biopsy rested on radiological and/or pathological suspicion of radial scar. The core biopsy category was B3 in all but one, which was in the B1 category. In a further 10 patients, referral was based primarily on a pathological B3 categorisation. The reasons for this were as follows: papillary lesion (two), fibroepithelial lesion (two), atypical intraductal epithelial proliferation (two), stromal mucin (two), atypical lobular hyperplasia (one), and an unusual vascular lesion (one). Two cases with a C3 on FNAC also derived from papillary lesions. In the remaining nine patients, the radiological features were sufficiently suspicious to prompt referral in the presence of either inadequate/unrepresentative (C1/B1) or benign (B2) preoperative pathological findings. Two women had no preoperative needle biopsy.

Conclusions: In 22 of 36 benign biopsies, the initial core biopsy categorisation was B3. According to the current system of core biopsy categorisation, a diversity of lesions must be designated as of "uncertain malignant potential" (B3) because the technique provides insufficient tissue for full histological assessment. The use of this category may increase the number of benign biopsies if all such cases are referred for surgery. An increase in the benign biopsy rate may be averted if larger amounts of tissue can be obtained using newer vacuum assisted techniques such as the Mammotome.

See end of article for authors' affiliations

Correspondence to: Dr P J Carder, Department of Pathology, St James's University Hospital, Beckett Street, Leeds LS9 7TF, UK; paulrecorder@doctors.org.uk

Accepted for publication 6 October 2002

Histopathology 2003, **42**, 331–336

Excision biopsy findings of patients with breast needle core biopsies reported as suspicious of malignancy (B4) or lesion of uncertain malignant potential (B3)

A H S Lee, H E Denley, S E Pinder, I O Ellis, C W Elston, P Vujovic, R D Macmillan & A J Evans for the Nottingham Breast Team
Departments of Histopathology, Surgery and Radiology, City Hospital, Nottingham, UK

Date of submission 13 June 2003

" THE B3 GROUP IS MORE HETEROGENEOUS AND HAS A LOWER RATE OF MALIGNANCY (25 %)..."

L' INCIDENZA DI MALIGNITA' ALLA ESCISSIONE CHIRURGICA E' DIVERSA NELLE DIFFERENTI LESIONI

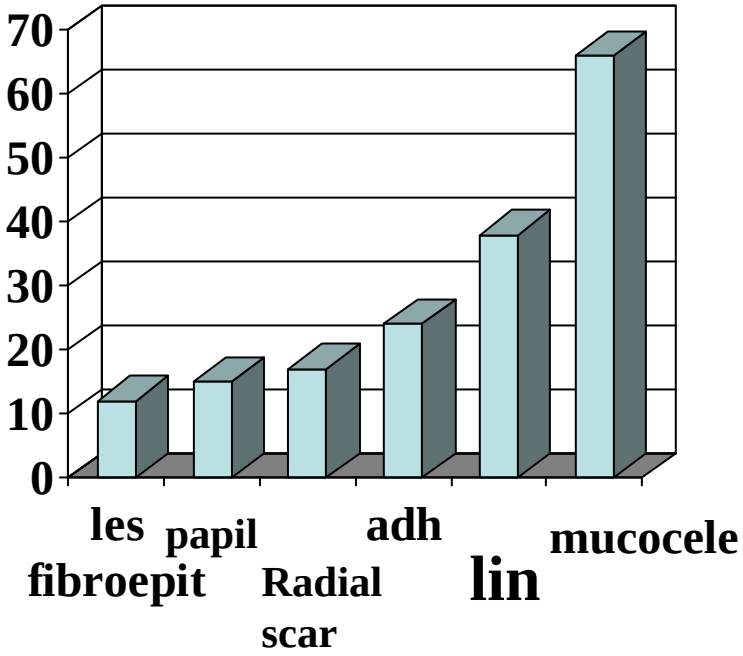

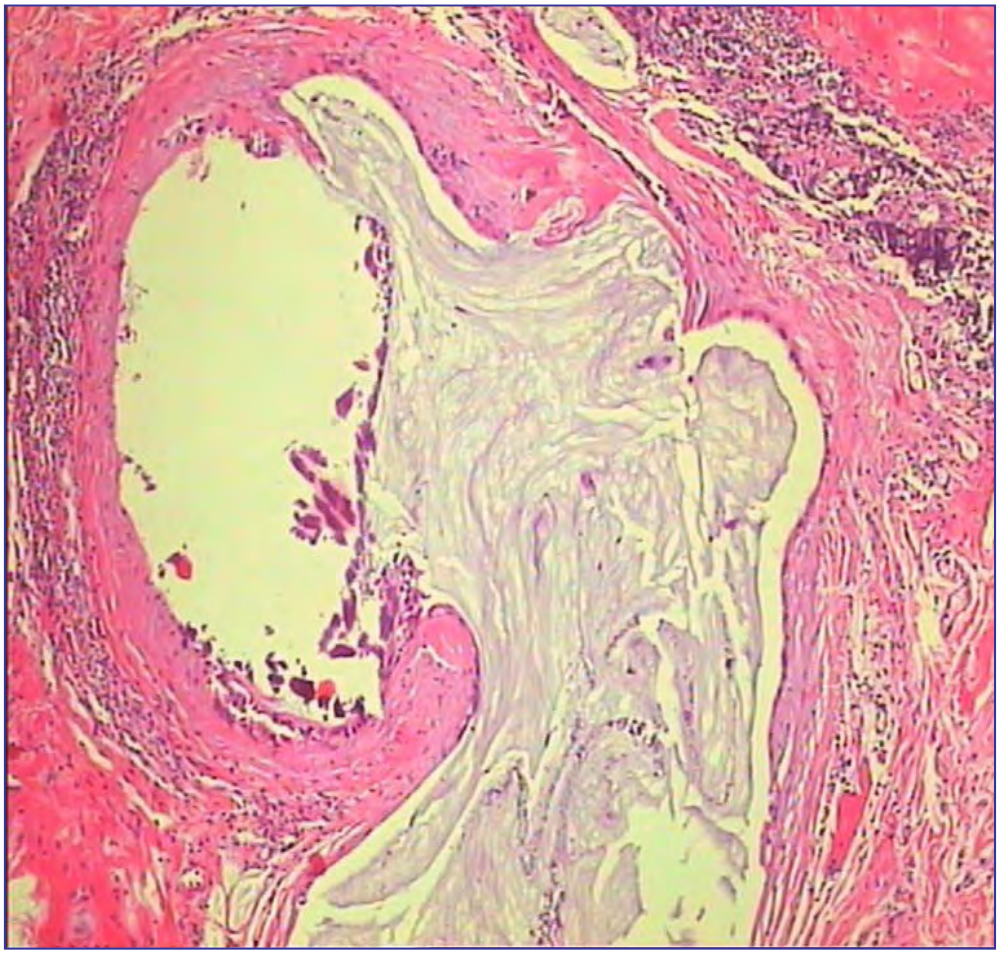

QUANTE SONO ?

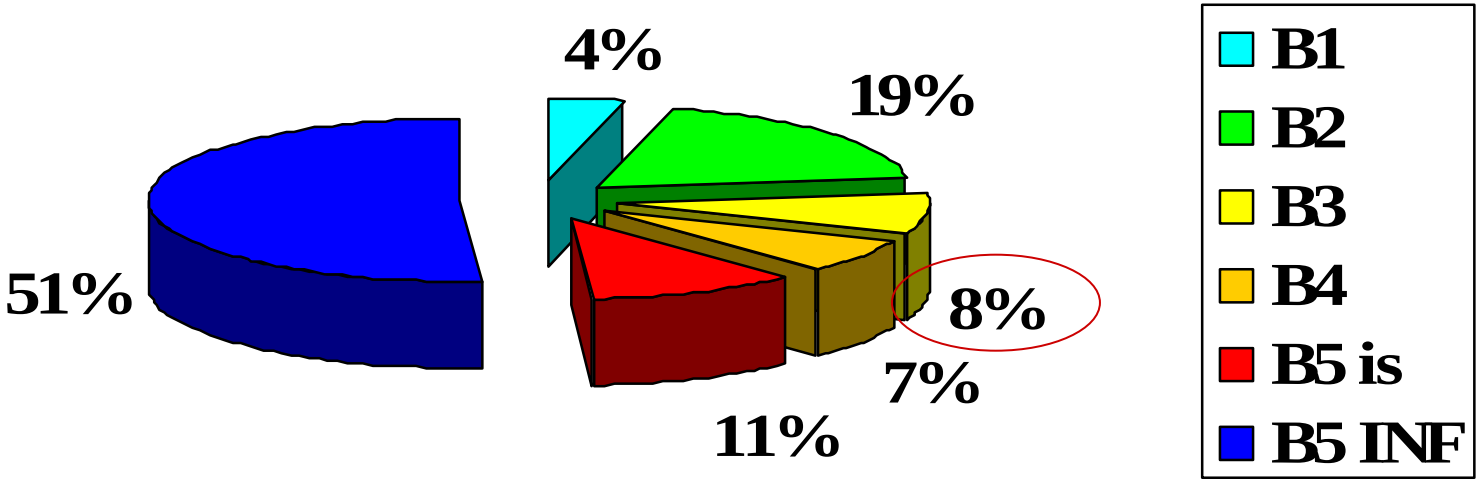

PERCHE' AD INCERTO POTENZIALE DI MALIGNITA' ?

1) Caratteristiche biologiche **intrinseche** alla lesione (NEOPLASIA LOBULARE)

2) Fattori **estrinseci** legati alla modalita' di prelievo bioptico: frammentazione della lesione, rappresentativita' del campione in esame (RADIAL SCAR)

3) Ridotta **riproducibilita'** diagnostica inter e intra osservatore (IPERPLASIA DUTTALE ATIPICA)

World Health Organization Classification of Tumours

Pathology & Genetics

Tumours of the Breast and Female Genital Organs

Edited by Fattaneh A. Tavassoli & Peter Devilee

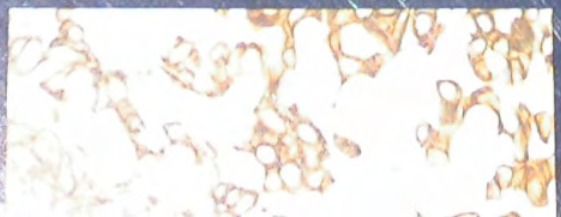

IPERPLASIA DUTTALE ATIPICA

DEFINIZIONE WHO, 2003:

A neoplastic intraductal lesion characterized by proliferation of evenly distributed monomorphic cells.

Cytologically, ADH corresponds to low grade DCIS.

There is currently no generally agreement on whether quantitative criteria should be applied to separate ADH from low grade DCIS.

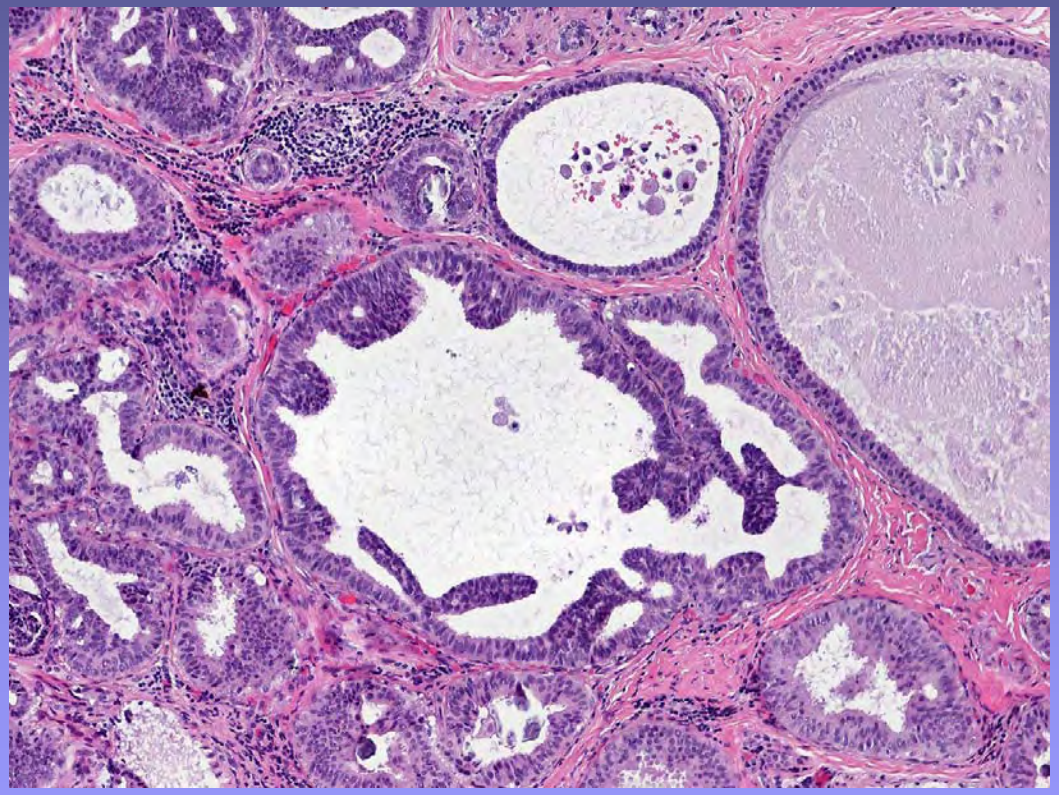

Synonims: Ductal intraepithelial neoplasia 1B (DIN 1B).

IPERPLASIA DUTTALE ATIPICA

Fattore di rischio per lo sviluppo di ca mammario (RR 4-5 volte)

(sec. Cancer Committee of the College of American Pathologists)

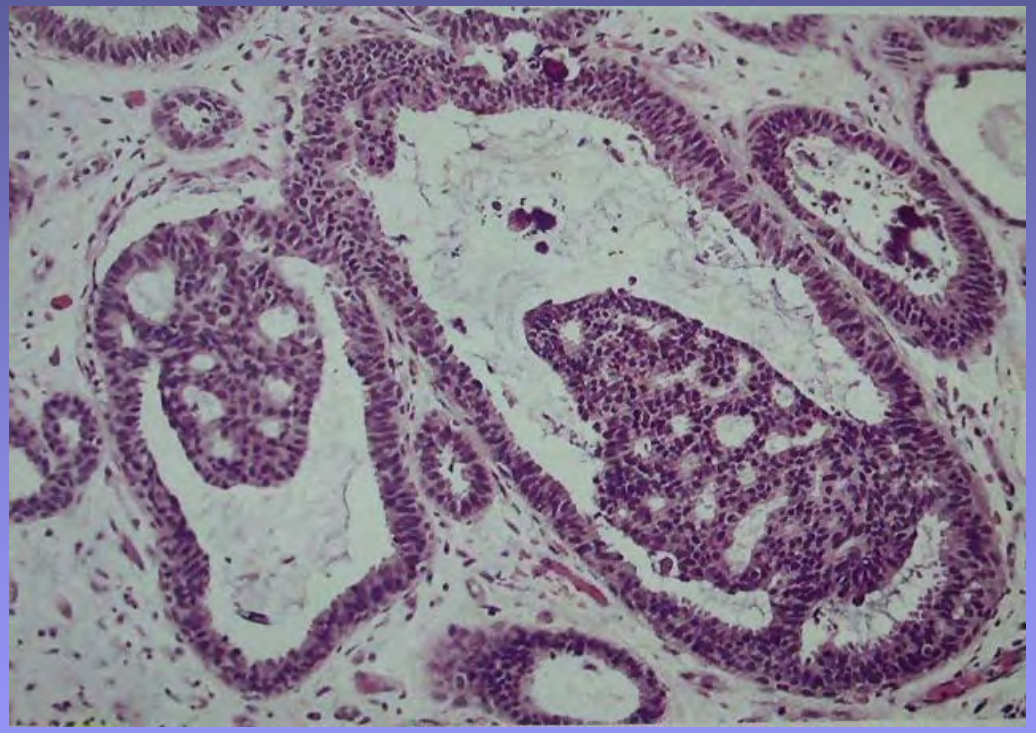

- Epiteliosi (usual ductal hyperplasia): RR 1.5-2

- Carcinoma duttale in situ (DCIS): RR 8-11

Table 1.11
Classification of intraductal proliferative lesions.

WHO, 2003

Traditional terminology	Ductal intraepithelial neoplasia (DIN) terminology
Usual ductal hyperplasia (UDH)	Usual ductal hyperplasia (UDH)
Flat epithelial atypia	Ductal intraepithelial neoplasia, grade 1A (DIN 1A)
Atypical ductal hyperplasia (ADH)	Ductal intraepithelial neoplasia, grade 1B (DIN 1B)
Ductal carcinoma in situ, low grade (DCIS grade 1)	Ductal intraepithelial neoplasia, grade1C (DIN 1C)
Ductal carcinoma in situ, intermediate grade (DCIS grade 2)	Ductal intraepithelial neoplasia, grade 2 (DIN 2)
Ductal carcinoma in situ, high grade (DCIS grade 3)	Ductal intraepithelial neoplasia, grade 3 (DIN 3)

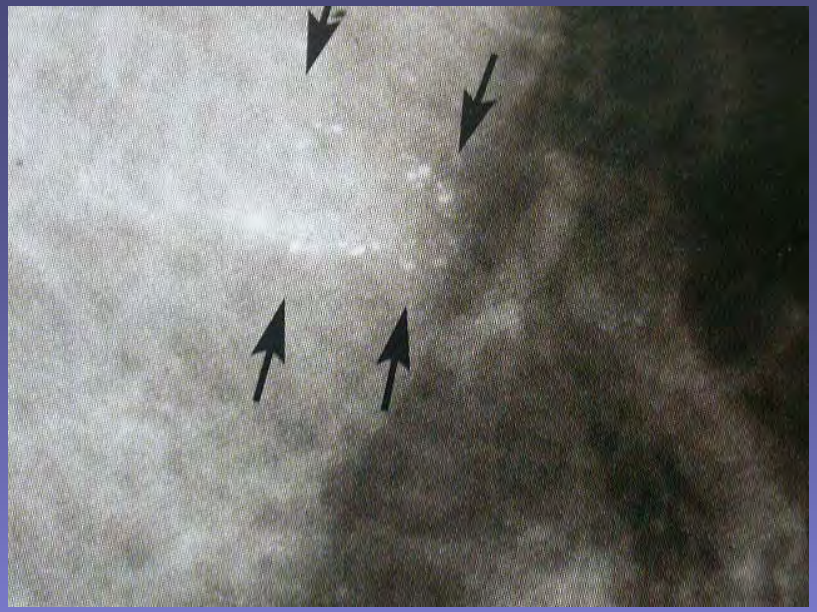

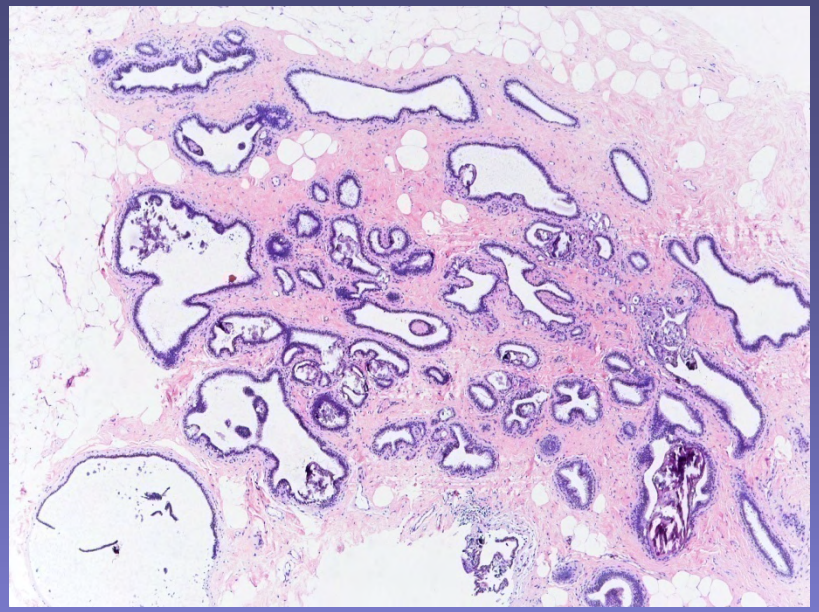

L' IPERPLASIA DUTTALE ATIPICA E' ASSOCIATA AD UNA SPECIFICA PRESENTAZIONE MAMMOGRAFICA

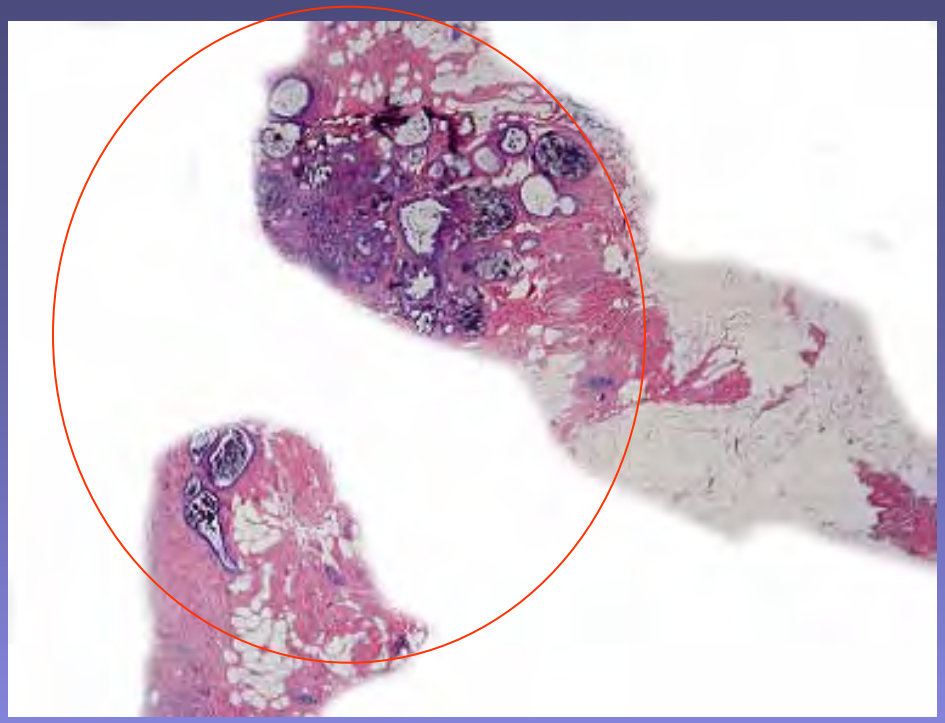

- SE IL FOCOLAIO E' MILLIMETRICO
- SE NON RESIDUANO MICROCALCIFICAZIONI
- SE NON CI SONO ALTRI FATTORI DI RISCHIO:

E' POSSIBILE FOLLOW-UP RADIOLOGICO

Flat epithelial atypia: A presumably neoplastic intraductal alteration characterized by replacement of the native epithelial cell by a single or 3-5 layers of mildly atypical cells.
Synonyms: Ductal intraepithelial neoplasia 1 A; clinging carcinoma; atypical columnar change

Table 1.11
Classification of intraductal proliferative lesions.

WHO 2003

Traditional terminology	Ductal intraepithelial neoplasia (DIN) terminology
Usual ductal hyperplasia (UDH)	Usual ductal hyperplasia (UDH)
Flat epithelial atypia	Ductal intraepithelial neoplasia, grade 1A (DIN 1A)
Atypical ductal hyperplasia (ADH)	Ductal intraepithelial neoplasia, grade 1B (DIN 1B)
Ductal carcinoma in situ, low grade (DCIS grade 1)	Ductal intraepithelial neoplasia, grade1C (DIN 1C)
Ductal carcinoma in situ, intermediate grade (DCIS grade 2)	Ductal intraepithelial neoplasia, grade 2 (DIN 2)
Ductal carcinoma in situ, high grade (DCIS grade 3)	Ductal intraepithelial neoplasia, grade 3 (DIN 3)

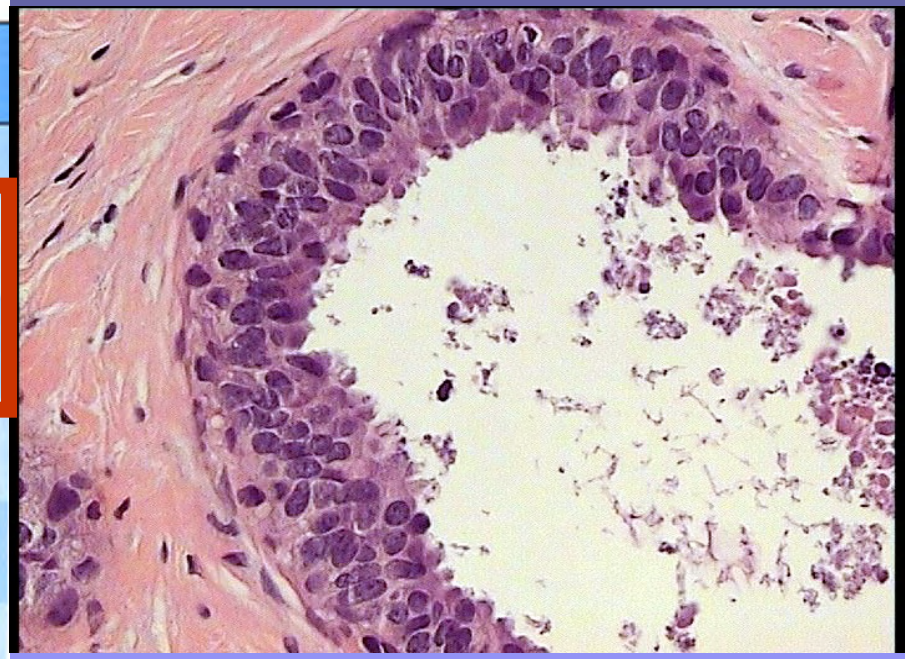

Maritza Martel, Patricia Barron-Rodriguez, Idris Tolgay Ocal, Jorge Dotto, Fattaneh A.Tavassoli. **Flat DIN 1 (flat epithelial atypia) on core needle biopsy: 63 cases identified retrospectively among 1,751 core biopsies performed over an 8-year period (1992-1999).**

Virchows Arch 451:883-891, 2007.

When flat DIN 1 is found on CNB as the most advanced lesion after mammographic correlation, an excisional biopsy is not mandatory; however close follow-up is advised with repeat mammograms.

NEOPLASIA LOBULARE (ALH AND CLIS)

DEFINIZIONE WHO, 2003:

Proliferation of generally small and often loosely cohesive cells, the term lobular neoplasia (**LN**) refers to **entire spectrum of atypical epithelial proliferations** originating in the terminal duct-lobular unit (TDLU).

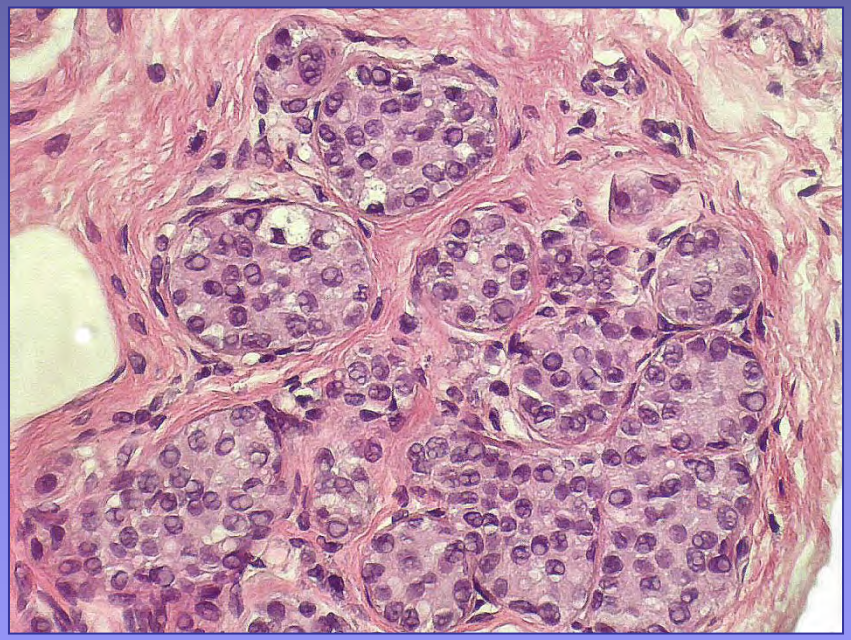

NEOPLASIA LOBULARE (ALH AND CLIS)

- Non ha una specifica presentazione mammografica
- Puo' associarsi a microcalcificazioni

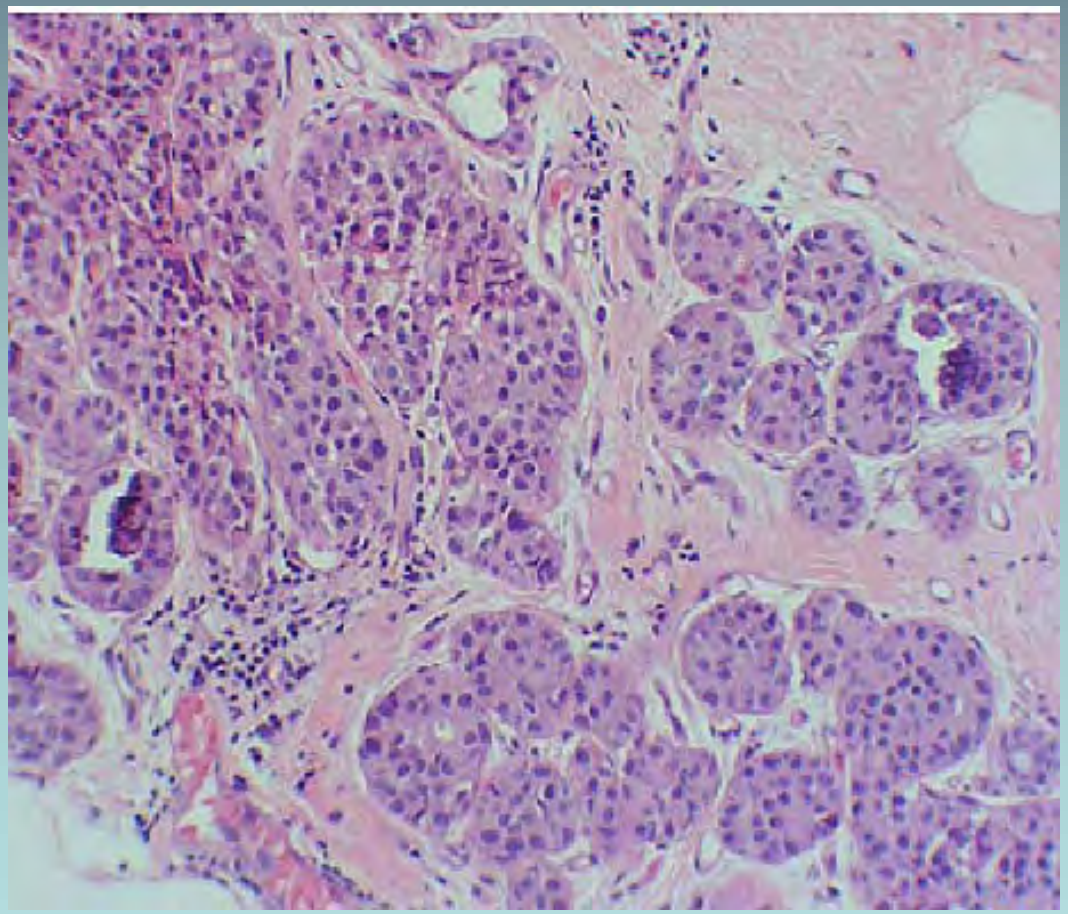

NEOPLASIA LOBULARE (ALH AND CLIS)

- Several molecular studies have challenged the prevalent theory that LCIS is only a marker of increased cancer risk, indicating that **lobular neoplasia may play a more direct role as a precursor of invasive carcinoma.**

  Lakani et al, 1995; Berx et al, 1996; Nayar et al, 1997; Lu et al, 1998

DG PREOPERATORIA DI NEOPLASIA LOBULARE: VA ESEGUITA BIOPSIA ESCISSIONALE ?

G.L.Bratthauer, F.A.Tavassoli.

Lobular intraepithelial neoplasia: previously unexplored aspects assesssed in 775 cases and their clinical implications. Virchows Arch (2002) 440:134-138.

38/92 (41%) casi di LIN 3 hanno ca invasivo o DIN 3 all'escissione

Follow-up Surgical Excision Is Indicated When Breast Core Needle Biopsies Show Atypical Lobular Hyperplasia or Lobular Carcinoma In Situ

A Correlative Study of 33 Patients With Review of the Literature

Tarik M. Elsheikh, MD and Jan F. Silverman, MD†*

Abstract: Atypical lobular hyperplasia (ALH) and lobular carcinoma in situ (LCIS) diagnosed in core needle biopsy (CNB) are generally regarded as risk indicators for developing invasive ductal or lobular carcinoma in either breast. Currently, there are no well-established guidelines for management of these patients. The most common management options are careful observation and endocrine chemoprophylaxis for high-risk patients. Previous studies had contradicting recommendations regarding follow-up surgical excision (FSE) of CNB yielding ALH or LCIS. These studies, unfortunately, have been limited by their retrospective nature, small number of patients examined, and association with other high-risk lesions. Only CNB diagnosed as pure LCIS or ALH (not associated with other high-risk lesions such as ADH, radial scar, or papilloma) were included in the study. We reviewed 33 CNB (20 ALH and 13 LCIS) with subsequent FSE from 33 patients (age range, 30–83 years; mean, 58 years). Eighteen of these patients were prospectively analyzed, where FSE was performed in an unselected fashion. All CNBs were obtained by mammotome (11-gauge, 30 cases; and 14-gauge, 3 cases). Mammography identified calcifications in 29 cases (88%) and a mass in 4 cases (12%). FSE revealed infiltrating ductal and/or lobular carcinoma in 4 of 13 LCIS (31%). FSE of 20 ALH revealed cancer in 5 cases (25%), including 4 ductal carcinoma in situ (DCIS) and 1 invasive lobular carcinoma. Several of these nine cancers were associated with calcifications, and two presented as masses. Sampling error and underestimation of cancer (DCIS or invasive carcinoma) was associated with CNB diagnosis of LCIS or ALH in 27% of all cases. Underestimation of cancer was seen in 28% of prospectively examined patients, including 20% of ALH and 38% of LCIS. CNB associated with mass lesions or that showed histologic features of pleomorphic LCIS or extensive classic LCIS had a higher rate of cancer underestimation. Despite removal of all abnormal mammographic calcifications by CNB in 6 patients, one cancer was detected on FSE. To the best of our knowledge, this is the largest study reported to date, and the only one to include prospectively examined patients with no pre-selection bias. Our data strongly suggests that subsequent FSE is warranted in all patients with CNB diagnoses of LCIS or ALH, to exclude the presence of cancer.

Key Words: needle core biopsy, lobular neoplasia, atypical lobular hyperplasia, lobular carcinoma in situ

(*Am J Surg Pathol* 2005;29:534–543)

From *Pathologists Associated/Ball Memorial Hospital Muncie, IN; and †Department of Pathology, Allegheny General Hospital, Pittsburgh, PA.
Correspondence: Tarik M. Elsheikh, MD, Pathologists Associated/Ball Memorial Hospital, 2401 University Avenue, Muncie, IN 47303 (e-mail: elsheikht@palah.com).

Lobular neoplasia encompassing atypical lobular hyperplasia (ALH) and lobular carcinoma in situ (LCIS) diagnosed by core needle biopsy (CNB) is generally regarded as a risk factor or a marker for developing invasive ductal or lobular carcinoma in either breast. Usually, patients with pure LCIS are not considered to need further treatment. However, more recent literature has challenged this view, indicating that lobular neoplasia may play a more direct role as a precursor of invasive carcinoma. The uncertainties concerning the biologic significance of a CNB diagnosis of LCIS or ALH have created considerable confusion and controversy regarding their management. Currently, there are no well-established guidelines for the management of these patients. The most common option is careful observation, and more recently, endocrine chemoprophylaxis for high-risk patients. We reviewed 33 CNBs from 33 patients with the diagnosis of pure LCIS or ALH. Follow-up wider surgical excision was available on all cases. Clinical and histopathologic findings are presented. Review of the literature and recent developments in the understanding of this controversial issue, as well as recommendations for management, are discussed.

MATERIALS AND METHODS

Breast CNBs with the diagnosis of pure LCIS or ALH (not associated with other high-risk lesions such as ADH, radial scar, papillary lesion, etc) were retrieved from the files of Pathologists Associated at Ball Memorial Hospital (28 cases) and Allegheny General Hospital (5 cases) between the years 1997 and 2003. The study included 33 CNB of nonpalpable mammographic abnormalities from 33 women with follow-up wider surgical excision (FSE). The patients ranged in age from 30 to 83 years (mean, 58 years). Six cases (5 ALH + 1 LCIS), not included in the study, had no FSE. Three of these patients had CNB diagnoses of ALH and showed no mammographic interval changes on clinical follow-up, ranging from 2 to 4

RADIAL SCAR / LESIONI SCLEROSANTI COMPLESSE

- NHSBSP, June 2001: ...unless the sclerosing lesion is very widely sampled, B3